

ORIGINAL ARTICLE

Angelito Braulio de Venecia III, MD
Ruben Lim Bon Siong, MD

Department of Ophthalmology
and Visual Sciences
University of the Philippines–Philippine
General Hospital
Manila, Philippines

Demodex sp. infestation in anterior blepharitis, meibomian-gland dysfunction, and mixed blepharitis

ABSTRACT

Objective

This study determined the incidence and density of *Demodex* species on the eyelashes of subjects with normal eyelids, anterior blepharitis (AB), meibomian-gland dysfunction (MGD), and mixed blepharitis (MB).

Methods

Consecutive patients diagnosed with AB, MGD, and MB were recruited, along with 50 normal individuals who served as controls. All underwent a standard eye exam. Data on demographics and ocular symptomatology were gathered. Digital photographs of the lid margins were taken. Lash sampling was done using the modified Coston procedure for epilating lashes. The collected lashes were checked for *Demodex* based on morphology and motility, and the total number of *Demodex* identified were tabulated for each eye. Patients with AB and MB had eyelid bacterial culture. Data were subjected to statistical analyses.

Results

A total of 167 patients with mean age of 53.7 years were included: 40% with MGD, 12% with AB, 19% with MB, and 30% normal. The overall incidence of *Demodex* infestation was 73%; 85% for MGD, 95% for AB, 97% for MB, and 34% for control group. The mean density count (MDC) was 13.63 for MB, 8.95 for AB, 4.08 for MGD, and 0.98 for the normal group. The incidence and density of *Demodex* infestation increased with age. Symptoms of irritation correlated with high MDC (>9 mites) ($p < 0.04$). Asymptomatic patients had low MDC (0 to 2 mites) ($p < 0.01$). Sixty-eight percent of patients with cylindrical dandruff ($p < 0.001$) and 36.1% with plugged meibomian glands ($p < 0.001$) had high MDC, while 82.7% with no eyelash findings had low MDC ($p < 0.001$).

Conclusion

The incidence and density of *Demodex* infestation was highest among patients with AB and MGD. Lid irritation and presence of cylindrical dandruff were indicative of high density count. These should alert the clinician to treat concomitant *Demodex* infestation of the eyelashes.

Keywords: *Demodex*, Meibomian-gland dysfunction, Anterior blepharitis, Mixed blepharitis

Correspondence to

Angelito Braulio Flores de Venecia III MD
Department of Ophthalmology and Visual Sciences
University of the Philippines–
Philippine General Hospital
Taft Avenue, Ermita
1000 Manila, Philippines
Telephone : +63-2-3022488
Fax : +63-2-3022491
E-mail : bellyboydv@yahoo.com

No financial assistance was received for this study.

The authors have no proprietary or financial interest in any product used or cited in this study.

Presented at the annual meeting of the Philippine Academy of Ophthalmology, Manila, Philippines, November 2010.

BELONGING to Phylum Arthropoda, Class Arachnida, Order Acarina, *Demodex* mite is an external parasite that can infest the meibomian and sebaceous glands. Although they normally inhabit the hair and eyelash follicles in low numbers, their over proliferation may lead to lid-margin infection causing ocular-surface irritation and symptoms of ocular discomfort like itching, foreign-body or stinging sensation. It may also exacerbate coexisting lid-margin diseases like anterior blepharitis (staphylococcal and sebaceous) and posterior blepharitis (meibomian-gland dysfunction). *Demodex* infestation is an often-overlooked differential diagnosis in the clinical investigation of blepharitis and may be a cause of treatment failure when not specifically addressed. The exact relationship of *Demodex* and blepharitis, however, is yet to be fully explained.

The adult *Demodex* is cigar-shaped, with several pairs of legs, and has a mouth with a biting apparatus. It measures about 280 to 440 microns. Two distinct species have been found on human skin: *Demodex folliculorum* and *Demodex brevis*.¹ Diagnosis of *Demodex* infestation is made by identification of the parasite at the root of the lashes using light microscopy.

Alejo and Valenton described *Demodex folliculorum* in the lids of 50% of randomly chosen Filipino patients at the Philippine General Hospital.² Patients diagnosed with blepharitis had *Demodex* in 88% of cases. The authors, however, did not classify blepharitis according to anatomic involvement or specific diagnosis of blepharitis, and did not associate age, sex, ocular symptomatology and clinical findings with the incidence and severity of *Demodex* infestation. Such correlation will be useful to the clinician in the diagnosis and treatment of blepharitis in general and *Demodex*-related blepharitis in particular.

This study determined the incidence and density of *Demodex* species found on the eyelashes of subjects with normal eyelids, anterior blepharitis, meibomian gland dysfunction, and mixed blepharitis. Specifically, it determined the relationship of the incidence and density of *Demodex* with age and sex, ocular symptoms related to blepharitis, and clinical lid-margin findings (dandruff-like material, collarette or cylindrical dandruff, scurf, plugged meibomian gland orifices, crust).

METHODOLOGY

Consecutive patients who consulted at the General Clinic and the External Disease Clinic of a tertiary public hospital over a period of 3 months with the diagnosis of meibomian-gland dysfunction (MGD), anterior blepharitis (AB), or mixed blepharitis (MB) were recruited into the study. One of the authors (ABDV) established the diagnosis based on preset criteria of clinical findings (Table 1) using a single slit lamp biomicroscope (Topcon

Table 1. Criteria for the diagnosis of MGD, anterior blepharitis (AB), and mixed blepharitis (MB).

Diagnosis	Findings on slitlamp biomicroscope
Normal	No findings of MGD or AB
MGD	Presents with all of the following: <ol style="list-style-type: none"> 1. Prominent meibomian gland orifices presenting as white plugs of keratin in the posterior eyelid 2. Turbid and viscous secretions presenting as foamy tear meniscus in the lower lid
AB	Presenting with 1 of the following: <ol style="list-style-type: none"> 1. Collarettes presenting as hard matted crusts surrounding the lash, plus any of the following: <ol style="list-style-type: none"> a. Ulceration in the anterior lid margin b. Cylindrical dandruff c. Telangiectasia in the lid margin (anterior or posterior) d. Poliosis e. Madurosis f. Trichiasis 2. Oily or greasy dandruff-like scales in the lid margin or lashes
MB	Presents with findings of MGD and AB

Slitlamp SLD7, Japan). The diagnosis was confirmed by one of the consultants of the External Disease Clinic (RLBS included) using the same slitlamp biomicroscope. Patients who were on topical ophthalmic medications over the past 3 months, except for artificial tears; with history of ocular or eyelid trauma and surgery; with previous diagnosis of chemical burns; Steven-Johnson syndrome, ocular cicatricial pemphigoid, and other similar conditions; with eyelid malpositions like entropion, ectropion, and dystrichiasis; or with signs of active ocular infection or inflammation other than blepharitis were excluded from the study. After the recruitment period for MGD, AB, and MB, 50 age-matched patients who consulted at the General Clinic for other eye complaints were recruited to serve as controls (normal).

All patients underwent standard eye examinations. Data gathered included demographics, ocular symptomatology, and clinical findings. Digital photographs of the lid margins were taken using the digital camera of the same slitlamp biomicroscope. Lash sampling was done using the Modified Coston Method for epilating lashes.⁶⁻⁷ The collected lashes were checked for *Demodex* based on morphology (Figure 1) using a light microscope (Nikon YS100) and the total number of *Demodex* identified were tabulated for each eye. Patients in groups AB and MB underwent eyelid culture using a standard procedure. Each eye was swabbed with a sterile cotton tip applicator on the upper and lower lid margins. Blood agar was used as the culture medium. The cotton-tip applicators were applied

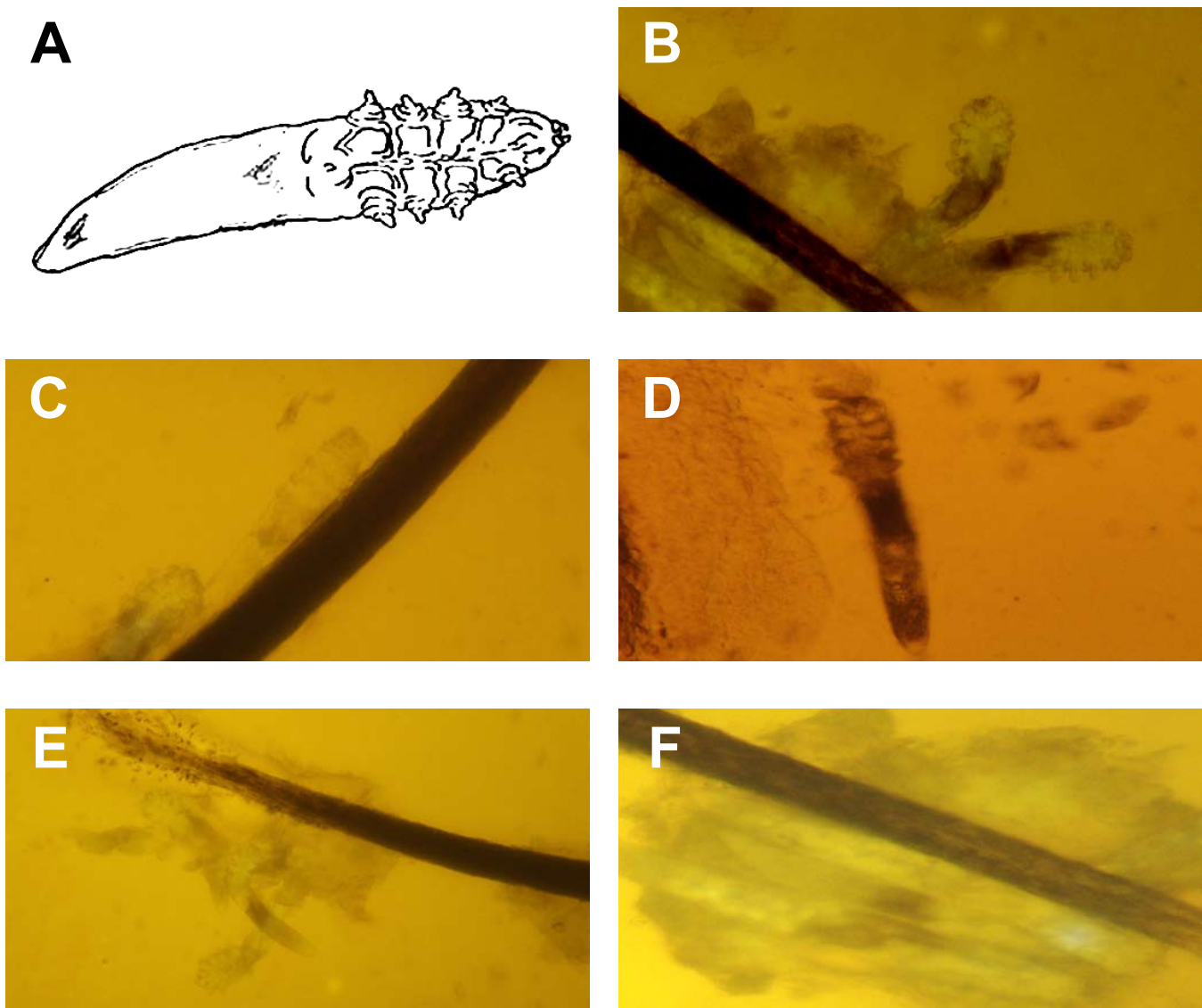


Figure 1. Appearance of *Demodex folliculorum* under the light microscope. The diagnosis of *Demodex* infestation is made by identification of the parasite under light microscopy. Diagram of a typical parasite that is cigar-shaped and has 4 pairs of short legs on the right half and a mouth with a biting apparatus on the extreme right (A). The parasite frequently appears in pairs and has an obvious head-neck part and body-tail part (B). The parasite is covered by a cuticle surface, and the body is mostly semi-transparent (C). The body-tail part may show numerous striations, while the head-neck part contain 4 pairs of short legs (D). *Demodex folliculorum* in clusters in a single hair follicle (E). *Demodex* embedded in dandruff-like debris (F).

to the blood agar plates. Specimen from the right eye was applied in the form of “R” and that of the left eye in the form of “L”. Each plate was labeled with the patient’s name and date of collection and sent to the Microbiology Department of UP-PGH for incubation and identification. All patients were referred back to either the General Clinic or the External Disease Clinic for further treatment and follow-up.

The main outcome measures were:

1. Incidence of *Demodex* infestation, taken as the percentage of patients per group (Normal, MGD, AB, MB) that had lashes with mites identified using the light

microscope, and

2. Mean *Demodex* count (MDC), taken as total number of mites counted from both right and left eyes of all patients of each group divided by the total number of patients per group.

Data were tabulated using Microsoft Excel ver. 2008 (Microsoft Corporation, Redmond, WA, USA). They were subjected to statistical analyses using one-way analysis of variance, Dunnett’s method of comparison (comparison with a control, $p < 0.01$), Tukey-Kramer HSD method, chi-square analysis, and *t*-test.

The study was reviewed and approved by the Ethics

Review Board of the University of the Philippines-Philippine General Hospital. Informed consent was obtained from all participants.

RESULTS

A total of 167 participants (334 eyes) were included, 22% males and 78% females with a mean age of 53.7 years (range, 20 to 85). Of the total, 50 (30%, 100 eyes) were normal; 65 (40%, 130 eyes) had MGD; 20 (12%, 40 eyes) had anterior blepharitis; and 32 (19%, 64 eyes) had mixed blepharitis.

Incidence of *Demodex* infestation

A total of 122 participants (73%) had *Demodex* infestation. The incidence of *Demodex* infestation was as follows: 34% (17/50) in normal participants, 85% (55/65) in MGD patients, 95% (19/20) in AB patients, and 97% (31/32) in MB patients (Figure 2). Using one-way ANOVA, there was a significant difference in the number of patients with *Demodex* infestation in MGD, AB, and MB compared to the normal group ($p < 0.01$).

There was a strong association between anterior and posterior blepharitis and *Demodex* infestation. The incidence was highest when both anterior and posterior blepharitis were present (MB), followed by posterior blepharitis (PB) and anterior blepharitis (AB).

Mean *Demodex* Count (MDC)

Patients with MB had the highest density of *Demodex* infestation, with MDC of 13.63 (range, 0 to 27), followed by AB with MDC of 8.95 (range, 0 to 22), and by MGD with MDC of 3.83 (range, 0 to 11). The normal group had the least density with MDC of 0.98 (range, 0 to 5) (Figure 3). The MDCs of MGD, AB, and MB were significantly different from the MDC of the normal group using the Dunnett's method of comparison ($p < 0.01$). The MDCs

of MGD, AB, and MB were also statistically different from each other.

The degree of blepharitis was directly proportional to the density count of *Demodex*. Mixed blepharitis with involvement of both anterior and posterior lid margins had the highest density counts. Comparing the incidence and MDC per diagnosis, it also showed a directly proportional relationship.

Relationship with Age

Majority of patients were between 41 and 70 years old (Figure 4). 58% of normal, 66% with MGD, 70% with AB, and 82% with MB were within this age range. The highest incidence of *Demodex* infestation was seen in the 61 to 70 age group (31%), followed by the 51 to 60 age group (24%) (Figure 5). One-way ANOVA test, however, showed no significant difference in the incidence of *Demodex* infestation among the different age groups. There was, likewise, a trend towards increasing density of *Demodex* (MDC) with increasing age (Figure 6). Using the Tukey-Kramer HSD Method, however, there was also no significant difference in density of *Demodex* among age groups.

These results showed possible direct relationship between age and incidence of *Demodex* infestation and between age and density of *Demodex*.

Relationship with sex

In all 4 groups, there were more female than male patients. The male: female ratio was 1:2 for normal, 1:5 for MGD, 1:5 for AB, and 1:3 for MB (Figure 7). The incidence of *Demodex* infestation was expectedly higher in females. However, taken as a percentage of patients of the same sex, there were 27 out of the total 37 males (73%) in the study found to be positive for *Demodex*. In females, 95 out of the 130 females (73.10%) were

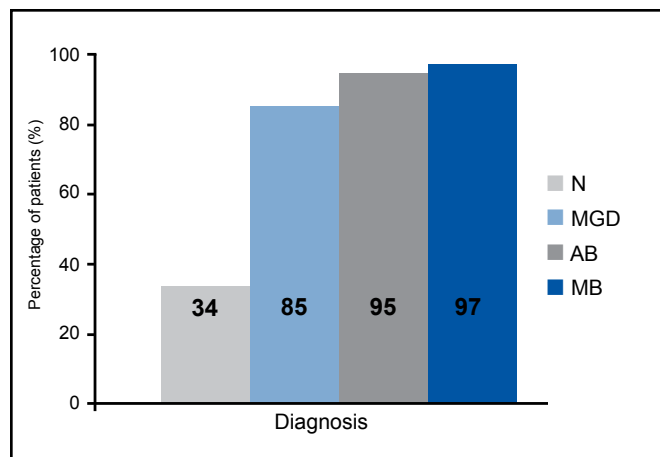


Figure 2. Incidence of *Demodex* infestation by diagnosis.

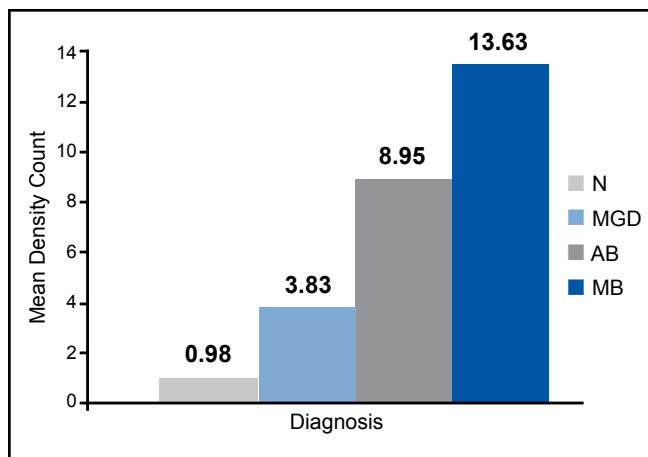


Figure 3. Comparison of mean density count of *Demodex* species by diagnosis.

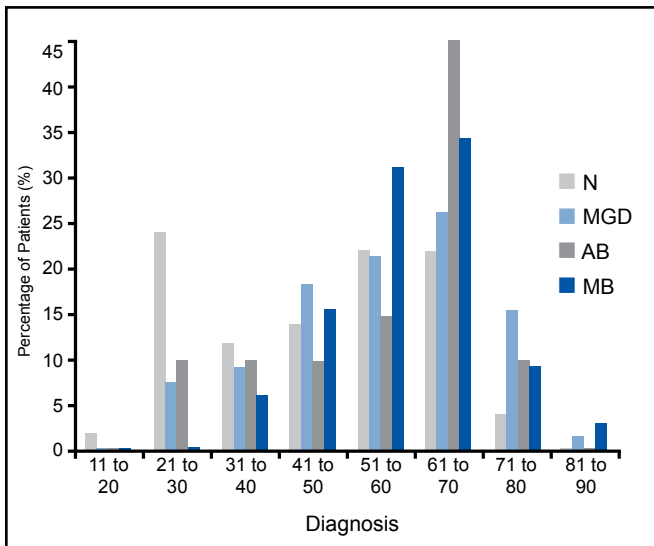


Figure 4. Age distribution of patients by diagnosis.

found to be positive for *Demodex* (Figure 8). Result of the one-way ANOVA test showed that the difference in the incidence of *Demodex* infestation between genders was not statistically significant. Similarly, one-way ANOVA test comparing MDC in males (5.65) and MDC in females (5.33) showed no significant difference.

These results showed that males and females, regardless of type of blepharitis, were equally at risk for *Demodex* infestation.

Relationship with ocular symptomatology

The most common eye symptoms were itchiness and foreign-body sensation (Table 2). These and other symptoms were nonspecific, appearing in all study groups.

Ocular symptomatology was compared with density of *Demodex* infestation (MDC) divided into four density ranges based on the data from Figure 3 (Table 2). Chi-square analysis was used to test if there was a difference in frequency of occurrence of symptom between the MDC ranges. Analysis showed that 50% of the patients with irritation had a MDC >9 mites ($p = 0.05$) and that 68.8% of patients with no symptoms had a MDC of 0 to 2 mites ($p = 0.01$). Other symptoms were similar in terms of their distribution in each of the MDC subgroups.

The results showed that:

1. Severe *Demodex* infestation, defined as presence of more than 9 mites, will probably result in lid irritation. Presence of *Demodex* usually did not present with any specific symptoms unless infestation was severe.

2. Individuals who were asymptomatic had no or very mild *Demodex* infestation.

3. Symptoms in *Demodex*-related blepharitis was not reflective of the severity of *Demodex* infestation.

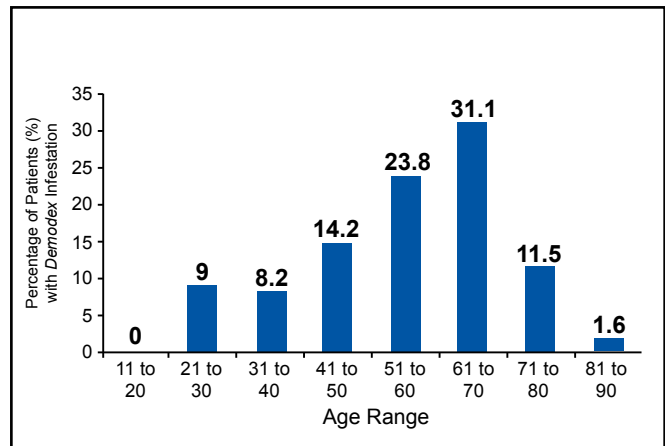


Figure 5. Relationship of age and incidence of *Demodex* infestation.

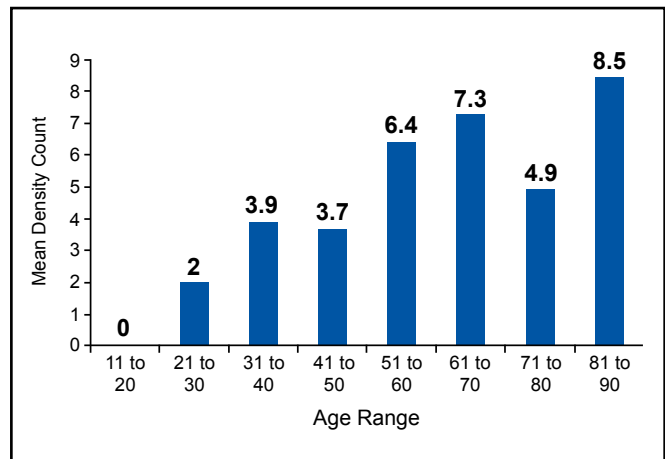


Figure 6. Relationship of age and density of *Demodex* infestation.

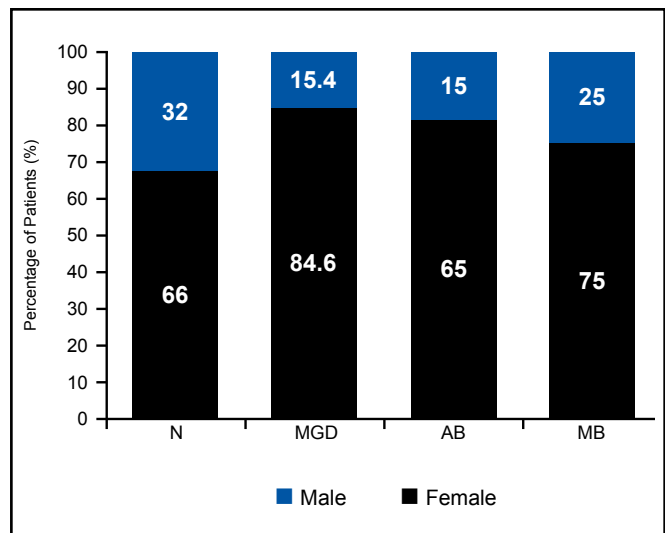


Figure 7. Gender distribution by study groups.

Relationship with clinical findings on slitlamp examination

Among the 3 groups of patients with diagnosis of blepharitis or MGD, the top 3 slitlamp lid-margin findings were collarettes/cylindrical dandruff, plugged meibomian gland orifices, and dandruff-like or scale-like materials. Clinical findings of collarettes/cylindrical dandruff had the highest association with the severity of the MDC, followed by plugged meibomian gland orifices (also seen in low MDC), while dandruff-like material was not associated with the severity of the density count (Table 3). Chi-square analysis showed that 68% of the patients with collarettes/cylindrical dandruff ($p < 0.001$) and 36.1% of plugged meibomian glands had a MDC > 9 mites ($p < 0.001$), and that 82.7% of patients with no clinical findings had a MDC of 0 – 2 mites ($p < 0.001$). Other clinical findings were similar in terms of their distribution in each of the MDC subgroups.

These results showed that:

1. Patients with clinical findings of collarettes/cylindrical dandruff or plugged meibomian gland orifices will probably have severe *Demodex* infestation.
2. Individuals with no clinical findings will have no or very mild *Demodex* infestation.
3. Clinical findings of dandruff-like materials are not reflective of the severity of *Demodex* infestation.

Culture Studies

Over 90% of cases in the AB and MB groups were positive for *Staphylococcus aureus* and *epidermidis* (Table 4). These findings supported the clinical diagnoses of anterior and mixed blepharitis among these patients.

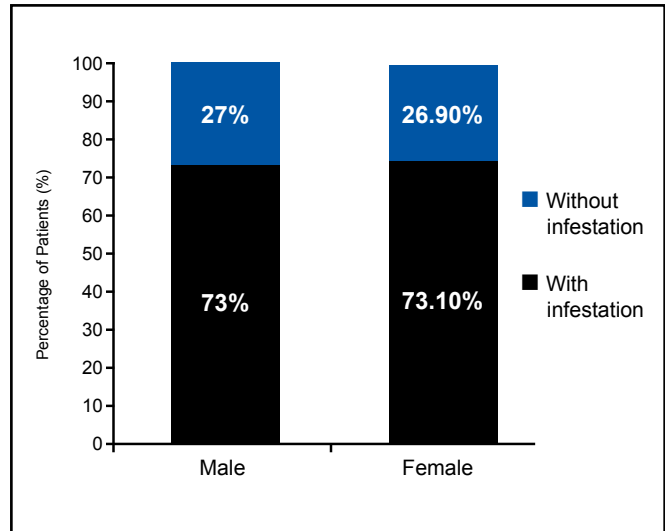


Figure 9. Gender distribution of patients with *Demodex*.

DISCUSSION

The general incidence rate of *Demodex* infestation in this study was 73%, significantly higher than the 50% in the study by Alejo and Valenton.² This could be partly due to the bigger sample size and the larger number of patients with anterior and posterior blepharitis included in the sampling. Among normal patients, the incidence was lower at 34%. In patients diagnosed with blepharitis, Alejo and Valenton found *Demodex* in 88% of cases, which is consistent with our study (85 to 97%). Their study, however, neither classified blepharitis according to anatomic involvement nor determined the density of the *Demodex*.

Table 2. Comparison between ocular symptomatology and density of *Demodex* (MDC=mean density count).

Ocular symptomatology	# of patients with symptom	Percentage of patients (%) with symptom per MDC range				p
		0 – 2 Mites	3 – 5 Mites	6 – 8 Mites	> 9 Mites	
Irritation	12	16.7	8.3	25.0	50.0	0.05
Itchiness	103	38.8	20.4	14.6	29.1	0.07
Eyelid heaviness	27	33.3	18.5	22.2	29.6	0.20
Sticky or moist sensation of the lids	21	33.3	19.0	14.3	33.3	0.71
Mucous discharge	12	41.7	8.3	8.3	41.7	0.55
Foreign body sensation	93	41.9	18.3	10.8	29.0	0.74
Transient blurring of vision	4	75.0	0.0	25.0	0.0	0.34
Redness	12	16.7	33.3	8.3	41.7	0.16
Eye pain	2	0.0	0.0	50.0	50.0	0.22
Tearing	29	31.0	24.1	6.9	37.9	0.20
None	32	68.8	15.6	3.1	12.5	0.01

This study demonstrated the highest incidence and density in patients with mixed blepharitis, followed by anterior blepharitis. MGD patients have the lowest incidence and density among the three. This can be explained by the fact that patients with mixed and anterior blepharitis have involvement of the eyelashes because *Demodex* mites tend to be clustered to the roots of lashes.

Demodex infestation in humans was once thought to be of no clinical significance due to its nonpathogenic nature. Several authors, however, have concluded that *Demodex* infestation or demodocosis is related to blepharitis.^{3,8-11} But the exact pathogenic potential of *Demodex* mites remains unclear because a low number of *Demodex* can be found in the skin and lashes of asymptomatic individuals. It is thought that *Demodex* becomes pathogenic when it multiplies to cause or exacerbate ocular symptoms and lid-margin changes. No prior research has convincingly demonstrated whether a minimal number of mites must be present to produce symptoms. Of the ocular symptoms investigated, only lid irritation correlated with a high *Demodex* count. The etiology of lid irritation in *Demodex* infestation is an interplay of different factors. First, the biting apparatus of the parasite alone may cause lid irritation. Second, lid irritation is also caused by the lipolytic enzymes produced by the parasite to digest sebum, and by the accumulation of parasite excreta, resulting in the blockage of sebaceous glands that may lead to infection or the stimulation of the host's humoral responses and cell-mediated reaction. Third, secondary or concomitant microbial blepharitis is common in *Demodex* infestation, as the microorganisms may cling to the integuments of the parasites.⁴

The incidence and density of *Demodex* infestation tend to steadily

increase with the individual's age. This is consistent with the increasing incidence of mixed blepharitis and MGD in the older age groups. Similar to the results of our study, Özlem et al. reported no significant difference between mite positivity and negativity between genders.⁵

Gao, et al. noted that *Demodex* infestation was more prevalent in patients with clinically evident cylindrical dandruff, which was seen in anterior blepharitis.¹ The severity of *Demodex* infestation correlated well with the clinical finding of cylindrical dandruff. The *Demodex* count was higher in lashes with cylindrical dandruff compared to those without. English proposed that instead of just randomly choosing

non-adjacent lashes, as done in the conventional Coston Method, lashes with dandruff-like material should be picked over those without.⁶ This modification in the Coston Method was applied in this study. The conventional Coston method of determining *Demodex* infestation carried certain errors of under detection: (1) Random epilation of lashes may result in a lower count if lashes without cylindrical dandruff were epilated; (2) *Demodex* mites were more adherent to cylindrical dandruff and the non-adherent mites in lashes without cylindrical dandruff may get dislodge during mounting, resulting in undercounting.

The conventional Coston method of *Demodex* collection proposed in

Table 3. Comparison between clinical findings and density of *Demodex*.

Clinical findings on slit lamp examination	# of patients with finding	Percentage of patients (%) with symptom per MDC* range				p
		0 – 2 Mites	3 – 5 Mites	6 – 8 Mites	> 9 Mites	
Dandruff-like materials	89	37.1	20.2	12.4	30.3	0.25
Collarettes/cylindrical dandruff	50	6.0	8.0	18.0	68.0	< 0.001
Scurfs	1	0	0	0	100	0.41
Plugged meibomian gland orifices	96	28.9	23.7	11.3	36.1	< 0.001
Crusts	0	0	0	0	0	N/A
None	39	87.2	12.8	0	0	< 0.001

*MDC = mean density count

Table 4. Culture results of anterior blepharitis (AB) and mixed blepharitis (MB) groups.

Organism in culture	AB		MB	
	# of patients	Percentage (%) of total	# of patients	Percentage (%) of total
<i>Bacillus cereus</i>	0	0	1	3.1
<i>Bacillus licheniformis</i>	1	5.0	0	0
<i>Penicillium sp.</i>	0	0	1	3.1
<i>Enterobacter hapneae</i>	0	0	1	3.1
<i>Staphylococcus aureus</i>	13	65	21	65.5
<i>Staphylococcal epidermidis</i>	6	30	8	25
<i>Streptococcus faecalis</i>	0	0	1	3.1

1967 also advocated the use of peanut oil in mounting the specimen prior to microscopic evaluation and counting.³ Placing oil did not promote instant breakdown of debris and cuffs, resulting in undercounting of embedded mites. The use of fluorescein in our study improved the microscopic visibility and counting of *Demodex* by dissolution and expansion of cuffs. The yellowish contrast provided by the fluorescein also helped detect *Demodex* embedded in compact and opaque cuffs of epilated lashes, resulting in a more accurate *Demodex* count.⁷

The modified Coston method may still result in some under-counting especially in patients with MGD because it may not detect *Demodex brevis* since they burrow deep into the sebaceous and meibomian glands. Expressing sebum from plugged meibomian glands, and detecting *Demodex* microscopically, is a method to diagnose demodecosis in posterior blepharitis, although there are no previous studies to prove its efficacy. Biopsy of the lid margin is still the gold standard in detecting demodecosis, but this is an invasive procedure and not warranted for all forms of blepharitis unless malignancy is a strong consideration. Epilation of lashes is still a useful adjunctive tool to detect *Demodex* when the clinical presentation may not warrant the biopsy.

The incidence and density of *Demodex* infestation were highest among patients with both anterior blepharitis and meibomian-gland dysfunction. Symptom of lid irritation and presence of cylindrical dandruff are indicative

of high density count. These diagnoses and eye findings should alert the clinician about *Demodex* infestation of the eyelashes, especially in the elderly. Patients with recurrent blepharitis not responsive to current blepharitis treatment regimen should be investigated and treated for *Demodex* infestation.

References

1. Gao Y, Di Pascuale MA, Li W, et al. High prevalence of *Demodex* in eyelashes with cylindrical dandruff. *Inves Ophthalmol Vis Sci* 2005; 46: 3089-3094.
2. Alejo RLT, Valenton MJ, Abendanio R. *Demodex folliculorum* infestation of the lids in Filipinos. *Philipp J Ophthalmol* 1972; 4: 110-113.
3. Pena GP, de Souza J, Filho A. Is *Demodex* really non-pathogenic? *Rev Ins Med Trop S Paulo* 2000; 42: 171-173.
4. English FP, Nutting WB. Demodicosis of ophthalmic concern. *Am J Ophthalmol* 1981; 91: 362-372.
5. Özlem M, Aycan G, Otlu H, et al. Frequency of Demodicosis in various patients and age groups. *Türkiye Parazitoloji Dergisi* 2007; 31: 115-118.
6. English FP. *Demodex folliculorum* and edema of the eyelash. *Br J Ophthalmol* 1971; 55: 742.
7. Kheirkhah A, Blanco G, Casas V, et al. Fluorescein dye improves microscopic evaluation and counting of *Demodex* in blepharitis with cylindrical dandruff. *Cornea* 2007; 26: 697-700.
8. Liu J, Sheha H, Fu Y, Tseng SCG. *Demodex* blepharitis. *Advanced Ocular Care* May/June 2010: 37-39.
9. Türk M, Öztürk I, Sener AG, et al. Comparison of incidence of *Demodex folliculorum* on the eyelash follicle in normal people and blepharitis patients. *Türkiye Parazitoloji Dergisi* 2007; 31: 296-297.
10. Norm MS. *Demodex folliculorum*: Incidence and possible pathogenic role in the human eyelid. *Acta Ophthalmol (Suppl)* 1970; 108: 7-85.
11. Czeptia D, Kuzna-Grgiel W, Czepita M, Grobelmy A. *Demodex folliculorum* and *Demodex brevis* as a cause of chronic marginal blepharitis. *Ann Acad Med Stein* 2007; 53: 63-67.
12. Gutgesel VJ, Stern G, Hood I. Histopathology of MGD. *Am J Ophthalmol* 1982; 94: 383-387.