

ORIGINAL ARTICLE

Robert T. Ang, MD^{1,2}
Gladness A. Martinez, MD²
Jesse B. Caguioa, OD¹
Karen B. Reyes, MD^{1,2}

¹*Asian Eye Institute
Makati City, Philippines*

²*Cardinal Santos Medical Center
San Juan, Metro Manila, Philippines*

Comparison in the quality of vision and spherical aberration between spherical and aspheric intraocular lenses

ABSTRACT

Objective

This study compared the quality of vision and spherical aberration (SA) in eyes implanted with spherical and aspheric intraocular lenses (IOL).

Methods

Twenty-two patients (44 eyes) with bilateral cataracts were included in a prospective, comparative, randomized clinical study to receive either Alcon IQ aspheric or Natural IOL in either eye. Three-month postoperative evaluation included uncorrected (UCVA) and best-corrected visual acuity (BCVA), and contrast sensitivity under photopic and mesopic conditions.

Results

In the IQ group, UCVA was at least 20/20 in 45% and 20/40 in 85% of the eyes. High-contrast BCVA was at least 20/16 in 36%, 20/20 in 95%, and 20/40 in 100% of eyes. In the Natural group, UCVA was at least 20/20 in 35% and 20/40 in 95% of eyes. High-contrast BCVA was 20/16 in 40%, at least 20/20 in 95% and 20/25 in 100% of eyes. Mean spherical equivalent was $-0.15 \pm 0.6D$ in the IQ and $-0.25 \pm 0.6D$ in the Natural. The mean SA in the IQ was significantly lower than in the Natural ($0.15 \mu\text{m}$ vs. $0.49 \mu\text{m}$; $p < 0.001$). Mean total higher-order aberration was significantly lower in the IQ vs. the Natural ($0.58 \mu\text{m}$ vs. $0.75 \mu\text{m}$; $p = 0.03$). Contrast sensitivity under photopic and mesopic conditions did not show a significant difference between the groups.

Conclusion

UCVA, high-contrast BCVA, and contrast sensitivity at 3 months were comparable between eyes implanted with IQ and Natural IOL. Mean spherical and total higher-order aberrations were significantly lower in the IQ group.

Keywords: *Intraocular lens, Cataract, Phacoemulsification, Spherical aberration, Higher-order aberration*

Correspondence to

Robert T. Ang, MD
Asian Eye Institute
9/F Phinma Plaza, Rockwell Center
1200 Makati City, Philippines
Telephone : +63-2-8982020
E-mail : RTAng@asianeyeinstitute.com

No financial assistance was received for this study.

The authors have no proprietary or financial interest in any product used or cited in this study.

MODERN cataract surgery has advanced extensively, its aims no longer limited to the removal of the cataractous lens but extending to the improvement of vision through implantation of intraocular lenses (IOLs). Studies have shown that in a young eye without cataract, the cornea exerts a positive spherical aberration (SA) while the natural lens exerts a negative SA.¹⁻³ These tend to cancel each other out, producing a clear retinal image. With increasing age, however, the compensation afforded by the crystalline lens is gradually lost with the development of cataract, leading to an increase in total ocular higher-order aberrations (HOA).

Implantation of a spherical IOL has been the standard in phacoemulsification surgery. Spherical lenses provide good vision but have been shown to induce positive SA, yielding poorer image quality by decreasing contrast sensitivity.^{4,5} Aspheric lenses, such as the IQ lens (Alcon Laboratories, Fort Worth, TX, USA) were developed to lower spherical and total HOA of the optical system. The Alcon IQ lens incorporates a $-0.20\ \mu\text{m}$ SA that is presumed to offset the $+0.20\ \mu\text{m}$ SA of the cornea, resulting in neutral or significantly lower SA. Correcting the cornea's positive SA has been shown to improve contrast sensitivity.⁶

This study compared the quality of vision and SA in eyes implanted with the Alcon Natural and the Alcon IQ aspheric IOL.

METHODOLOGY

Twenty-two patients with bilateral cataracts seen from October 2006 to April 2007 were recruited for a prospective, comparative, randomized, subject-masked clinical trial in a single center. Included in the study were patients 45 years old and above with bilateral cataracts willing to undergo phacoemulsification with IOL implantation in both eyes. Their high-contrast best spectacle-corrected or potential-acuity-meter-tested vision should be at least 20/40 in both eyes. Patients were excluded if they had any of the following in either eye: greater than +3 brunescant cataracts, astigmatism greater than 1.50D detected by manifest refraction or corneal topography, increased intraocular pressure (IOP), narrow angles or diagnosed with glaucoma, symptomatic ocular-surface pathology such as dry eye, abnormal corneal topography (keratoconus), iris abnormalities, specular microscopy count less than 1,200 cells/mm², unstable zonules manifested by phacodonesis or pseudoexfoliation, history of traumatic eye injury, uveitis, ocular-muscle disorders, posterior-segment pathologies like diabetic retinopathy, and previous ocular or refractive surgery. Pregnant or lactating patients, those taking any form of steroids, patients with history of allergy to any medications used during and after phacoemulsification, those who had adverse events intraoperatively (i.e. vitreous loss or sulcus-

placed IOL) or who developed increased IOP postoperatively were also excluded. Depending on the contact lens used, patients were advised to discontinue use at least 1 to 3 weeks before preoperative testing.

The following tests were performed 30 days preoperatively: uncorrected and best-corrected visual acuity (UCVA and BCVA) with manifest refraction using high-contrast chart, applanation tonometry, slitlamp examination, corneal topography (Orbscan version 3.14, Bausch and Lomb, Germany), pupillometry (dim-light pupil size, Zywave version 5.20, Bausch and Lomb, Germany), biometry by 2 technicians using a Quantel Axis II version 1.07 A-scan (Quantel Medical, France), specular microscopy (SP1000, Topcon, Japan), dilated aberrometry (Zywave version 5.20, Bausch and Lomb, Germany), potential-acuity meter (Marco Technologies, USA) and a dilated-retina examination.

A randomization table was used to determine whether the Alcon Acrysof IQ or the Natural lens would be implanted in the first eye. The subjects were masked as to which IOL each eye received. The choice of IOL power was based on the surgeon's previous experience with a desired target of emmetropia.

Standard phacoemulsification was done by a single surgeon (RTA). The surgeries were performed under topical or retrobulbar anesthesia with sedation. After the procedure, appropriate topical antibiotic and steroid eye drops were administered at the discretion of the surgeon at a minimum duration of two weeks postoperatively. The second eye was operated within 2 weeks after the first operation.

The following tests were performed at 3 months postoperation: UCVA and BCVA with manifest refraction using high-contrast charts, contrast-sensitivity testing (photopic/daytime $-85\ \text{cd}/\text{m}^2$ and mesopic/nighttime $-3\ \text{cd}/\text{m}^2$) with and without glare using Optec 6500 (Stereo Optical Inc., Chicago, USA), slitlamp examination with IOP measurement, corneal topography, pupillometry (dim-light pupil size—Zywave readings), dilated aberrometry.

Postoperative visual perception was obtained by means of a questionnaire with a given score for each category. Distance vision during daytime, under normal lighting condition, and at night, including satisfaction in vision, were rated using the following scoring system: 5 = excellent, 4 = very good, 3 = average, 2 = poor, and 1 = bad. Symptoms of glare and haloes were rated at 5 = none, 4 = mild, 3 = moderate, 2 = marked, and 1 = severe. Higher mean scores implied better results whereas lower scores implied less satisfactory results. The mean score for each category was calculated and tested for significance.

Visual acuities were reported in Snellen equivalents. Differences between groups were analyzed using paired

two-tailed t-test. A *p* value of <0.05 was considered statistically significant.

The study protocol followed the Declaration of Helsinki and a written informed consent was obtained from each patient.

RESULTS

Forty-four eyes of 22 patients, 10 males and 12 females, were included in the study. The mean age was 64 years (range, 55 to 82). The mean preoperative UCVA was 20/60 in both groups (range, >20/200 to 20/25). The preoperative spherical equivalent ranged from -8.75D to +7.00D with a mean of -0.35D. Two patients were lost to follow-up at 3 months. The mean pupil size at 3 months was 5.1 mm for the IQ and 5.3 mm for the Natural group.

The UCVA at 3 months was similar in both groups (Figure 1). The mean spherical equivalent in the IQ was $-0.12 \pm 3.25D$ at preoperation, $-0.23 \pm 0.56D$ at 1 month, and $-0.15 \pm 0.6D$ at 3 months. The mean spherical equivalent in the Natural was $0.57 \pm 3.0D$ at preoperation, $-0.41 \pm 0.52D$ at 1 month, and $-0.26 \pm 0.6D$ at 3 months. Between the two groups, the mean spherical equivalent was similar at 3 months (Table 1).

At 3 months, high-contrast daytime BCVA without glare was 20/16, 20/20, and 20/25 in 36%, 95%, and 100% of eyes respectively in the IQ; and 20/16, 20/20, and 20/25 in 40%, 95%, and 100% of eyes respectively in the Natural.

Table 1. Mean spherical equivalent and aberration at 3 months.

	IQ	Natural	<i>p</i>
Spherical equivalent (diopter)	-0.15 ± 0.6	-0.26 ± 0.6	0.59
Spherical aberration (μm)	0.15 ± 0.17	0.49 ± 0.16	<0.001
Higher-order aberration (μm)	0.57 ± 0.23	0.75 ± 0.16	0.03

Table 2. Contrast sensitivity at 3 months.

	Spatial Frequency				
	1.5 cpd	3 cpd	6 cpd	12 cpd	18 cpd
Daytime (no glare)					
IQ	108	149	180	100	43
Natural	106	155	179	102	42
<i>p</i>	0.79	0.50	0.91	0.77	0.83
Daytime (with glare)					
IQ	108	138	168	98	39
Natural	102	138	168	93	35
<i>p</i>	0.34	0.97	0.96	0.55	0.39
Nighttime (no glare)					
IQ	97	118	143	64	21
Natural	92	113	134	61	16
<i>p</i>	0.57	0.72	0.59	0.75	0.18
Nighttime (with glare)					
IQ	79	91	91	33	9
Natural	72	85	80	31	9
<i>p</i>	0.36	0.56	0.39	0.66	0.77

Contrast-sensitivity results showed that in both photopic and mesopic studies, the mean scores at spatial frequencies of 1.5, 3, 6, 12, and 18 did not show significant differences between the groups (Table 2). Contrast-sensitivity scores under mesopic study with and without glare were higher in the IQ than in the Natural in all spatial frequencies, but the differences did not reach statistical significance.

The mean scores for postoperative visual perception for daytime, normal-light, and nighttime vision at 3 months were similar for both groups (Table 3). Symptoms of glare and haloes were similar. Satisfaction scores between the two groups were also equivalent (Table 3).

At 3 months, the mean SA was $0.15 \pm 0.17 \mu m$ in the IQ and $0.49 \pm 0.16 \mu m$ in the Natural; this difference was statistically significant (Table 1). The mean HOA of $0.57 \pm 0.23 \mu m$ in the IQ differed significantly from the $0.75 \pm 0.16 \mu m$ in the Natural (Table 1).

DISCUSSION

The mean UCVA, BCVA, and spherical equivalent were similar in the IQ and Natural groups in this study. Mean SA and HOA were, however, significantly lower in the IQ than in the Natural. Other studies have shown similar results, with a decrease in SA and HOA in aspheric lenses and improving the optical quality in pseudophakic patients.^{4,5,7} Contrast sensitivity was reportedly improved in both photopic and mesopic conditions.⁶⁻⁷ In this study,

Table 3. Visual-perception and satisfaction (mean scores).

	IQ	Natural	<i>p</i>
Visual Perception			
Daytime Vision	3.9	3.8	0.49
Normal Light	3.8	3.7	0.43
Nighttime Vision	3.3	3.2	0.43
Visual Satisfaction			
Glare	4.0	3.9	0.72
Haloes	4.4	4.3	0.33
Satisfaction	4.6	4.3	0.33

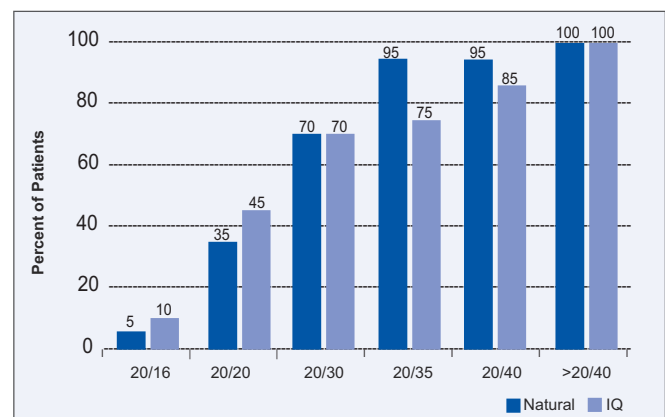


Figure 1. Uncorrected visual acuity at 3 months.

although the contrast-sensitivity scores under mesopic conditions with and without glare were higher in the IQ, the difference was not statistically significant. Clinically, the distance-vision perception of the patients under different lighting conditions and the visual-disturbances (glare, haloes) scores at 3 months were similar for both groups.

In summary, eyes implanted with the IQ aspheric IOL have a significantly lower spherical and total higher-order aberration compared to eyes implanted with the spherical Natural lens. This could benefit patients who require better nighttime vision or who may have large pupils in dim-light situations. Increasing the study population may also make the results, particularly contrast-sensitivity studies, more statistically significant.

References

1. Artal P, Berrío E, Guirao A. Contribution of cornea and internal surfaces to the change of ocular aberrations with age. *J Opt Soc Am* 2002; 19: 137-143.
2. Artal P, Guirao A, Berrío E, Williams DR. Compensation of corneal aberrations by the internal optics of the eye. *J Vision* 2001; 1: 1-8.
3. Barbero S, Marcos S, Merayo-Llodes J. Corneal and total optical aberrations in a unilateral aphakic eye. *J Cataract Refract Surg* 2002; 28: 1594-1600.
4. Holladay JT, Piers PA, Koranyi G, et al. A new intraocular lens design to reduce spherical aberration of pseudophakic eyes. *J Refract Surg* 2002; 18: 683-691.
5. Mester U, Dillinger P, Anterist N. Impact of a modified optic design on visual function: clinical comparative study. *J Cataract Refract Surg* 2003; 29: 652-660.
6. Marcos S, Barbero S, Jimenez-Alfaro I. Optical quality and depth of field of eyes implanted with spherical and aspheric intraocular lenses. *J Refract Surg* 2005; 21: 223-235.
7. Caporossi A, Martone G, Caspirini F, Rapisarda L. Prospective randomized study of clinical importance of 3 aspheric and 2 spherical intraocular lenses in 250 eyes. *J Refract Surg* 2007; 23: 639-648.