

# Inflammatory foveal mass and cystoid macular edema

Harvey S. Uy, MD

Asian Eye Institute  
Makati, Philippines

Sentro Oftalmologico Jose Rizal  
University of the Philippines–Philippine General Hospital  
Manila, Philippines

## ABSTRACT

### Objective

To report a case of inflammatory foveal mass and cystoid macular edema and the role of optical coherence tomography in its diagnosis and treatment monitoring.

### Methods

This is a case report of a healthy, young female who experienced sudden onset of wavy, blurring of vision. Clinical examination revealed an idiopathic, yellow, foveal mass and cystoid macular edema.

### Results

The condition resolved rapidly after treatment with oral corticosteroids suggesting an inflammatory nature. The vision returned to 20/20 after disease resolution.

### Conclusion

Optical coherence tomography was useful in diagnosing this disease condition and monitoring treatment response.

CYSTOID macular edema (CME) is a complication that may result from a wide variety of conditions including retinal vascular disorders, intraocular inflammation, vitreomacular traction, and ocular surgery or trauma. The presence of CME is established using fluorescein angiography (FA) and more recently, optical coherence tomography (OCT). We describe the ocular findings and disease course of a patient with CME associated with an idiopathic inflammatory foveal mass.

In August 2003, a healthy 21-year-old female presented with sudden, metamorphopsia and blurred vision in the right eye. The medical history, ocular history, and review of systems were unremarkable. On examination, the visual acuity was 20/30 in the right eye and 20/20 in the left eye. Amsler grid testing revealed distorted central vision in the right eye. The anterior-segment examination and

intraocular pressures of both eyes were normal. Biomicroscopic examination through a dilated pupil revealed a clear vitreous cavity and a small, yellow foveal mass with surrounding macular edema (Figure 1).

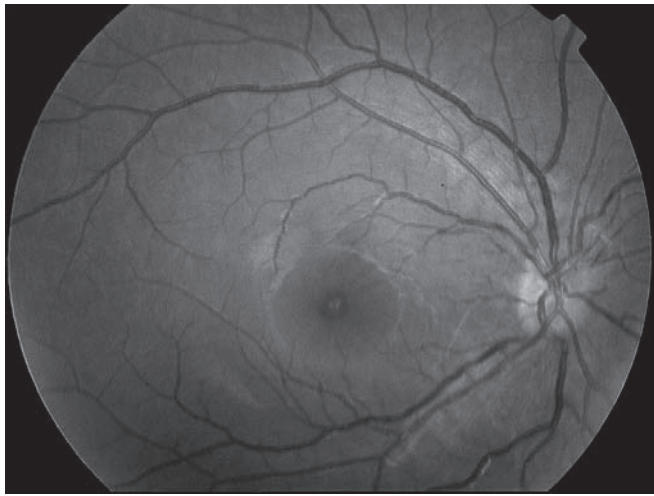
FA of the right macula revealed characteristic features of CME (Figure 2). OCT (Stratus OCT, Carl Zeiss Meditec, Dublin, CA, USA) revealed a solid, hyperreflective foveal lesion associated with multiple hyporefective intraretinal cystic spaces (Figure 3). The supplied retinal-thickness analysis software provided the following measurements: foveal thickness, 523  $\mu\text{m}$ ; mean central (1.0 mm) macular thickness, 596  $\mu\text{m}$ ; and, total macular volume, 9.43  $\text{mm}^3$ .

The patient was treated with oral prednisone (1 mg/kg/day), topical prednisolone acetate and topical diclofenac sodium. Visual acuity recovered to 20/20 and distorted vision resolved after 3 weeks of treatment. Repeat biomicroscopic examination revealed disappearance of the yellow foveal mass and return of the normal foveal reflex (Figure 4). A repeat OCT showed disappearance of the foveal mass and cystic spaces.

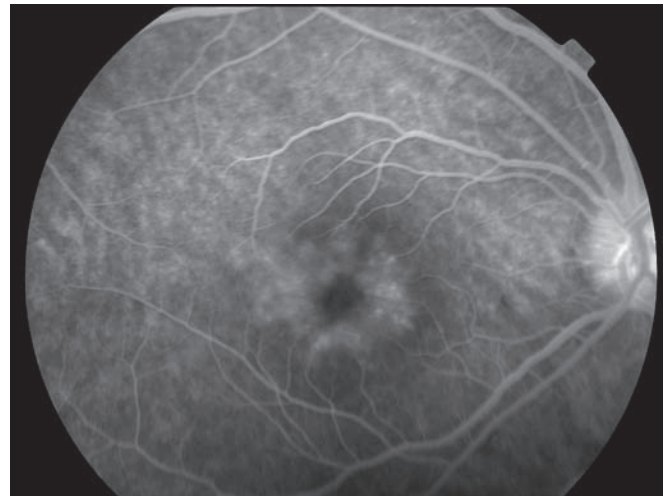
Oral prednisone and steroid eye drops were discontinued after one month and replaced with rofecoxib 25 mg/day (Vioxx, Merck, Whitehouse Station, NJ) as maintenance immunosuppressive medication. However, the patient discontinued rofecoxib on her own after 1 month which resulted in recurrence of distorted vision and CME. A second two-week course of prednisone (1 mg/kg/day) was completed with rapid recovery of vision. Rofecoxib was restarted and maintained for 6 months, then discontinued without recurrence of symptoms or development of drug-related adverse effects. The last OCT scan revealed a normal macular configuration and disappearance of the hyperreflective mass and cystic spaces (Figure 5). The final OCT measurements were: foveal thickness, 197  $\mu\text{m}$ ; mean central (1.0 mm) macular thickness, 234  $\mu\text{m}$ ; and, total macular volume, 8.1  $\text{mm}^3$ .

CME is a common, nonspecific pathologic response to disturbance of the blood-retinal barrier (BRB). Disruption of the tight junctions between the endothelial cells of the retinal vasculature or retinal pigment epithelial (RPE) cells results in extravasation of fluid and plasma proteins into the extracellular spaces of the retina. CME develops when fluid accumulation forms cystic spaces in the outer plexiform and inner nuclear layers of the parafoveal retina. Over time, these cystic spaces may coalesce, enlarge, and produce macular defects or holes. Disruption of Muller, photoreceptor, and RPE cell function has been shown to occur in CME and result in diminished visual acuity.<sup>1-5</sup>

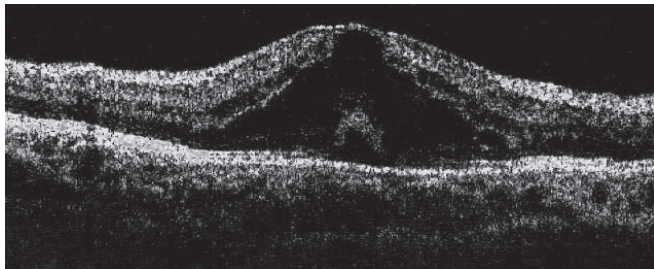
CME may develop from a variety of conditions, such as uveitis, diabetic and hypertensive retinopathy, venous occlusive disease, choroidal neovascularization, radiation retinopathy, vitreomacular-traction syndrome, epiretinal



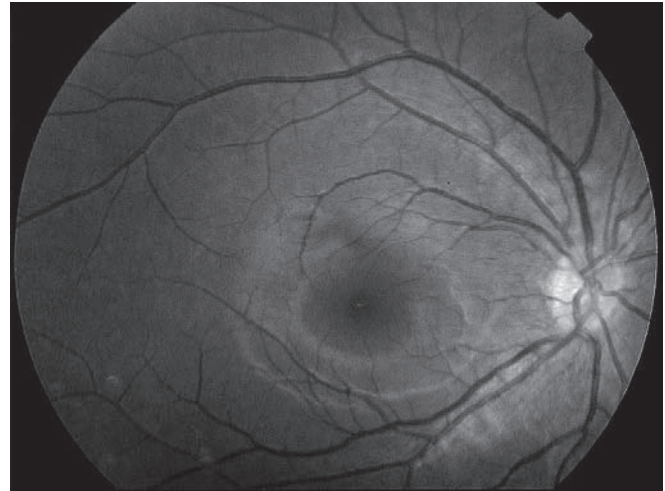
**Figure 1.** Fundus photograph shows a yellow foveal mass with surrounding cystoid macular edema.



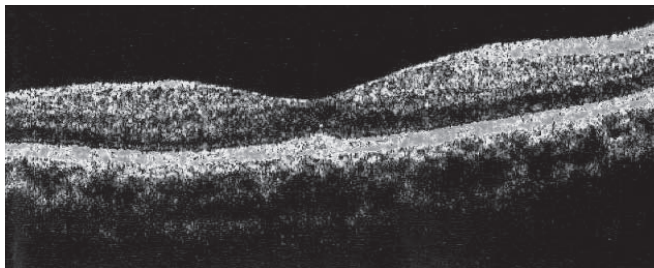
**Figure 2.** Fluorescein angiogram demonstrates parafoveal dye leakage and "petalloid" pattern of dye accumulation characteristic of cystoid macular edema.



**Figure 3.** Optical coherence tomography through the fovea shows a hyperreflective foveal mass with surrounding hyporeflexive cystic spaces resulting in foveal elevation.



**Figure 4.** After corticosteroid treatment, fundus photograph demonstrates return of normal foveal light reflex and disappearance of the foveal mass and cystoid macular edema.



**Figure 5.** After corticosteroid treatment, optical coherence tomography through the fovea demonstrates normal foveal depression and disappearance of the foveal mass and cystic spaces.

membrane, retinitis pigmentosa, and ocular trauma or surgery. In the case of uveitis, inflammatory mediators are believed to promote leakage from the BRB. The treatment of uveitis-associated CME is directed toward stopping the inflammatory process using immunosuppressive medications to eliminate production of inflammatory mediators and reestablish normal BRB function.<sup>6-7</sup>

FA is the principal diagnostic method for confirming the presence of CME. Leakage of sodium fluorescein from disrupted BRB followed by dye accumulation in the cystic spaces result in the characteristic "petalloid" or honey-

comb pattern seen in the angiogram. OCT is a relatively new imaging modality that analyzes reflected light from the retina to create highly detailed, cross-sectional images. In CME, hyporeflexive intraretinal cystic spaces are visualized by OCT. The analytical software supplied with the OCT machine can perform quantitative measurements of retinal thickness which is helpful for monitoring response to treatment.<sup>8</sup> In addition to being a sensitive method for detecting CME, OCT may demonstrate the presence of other pathologic conditions associated with CME, such as epiretinal membranes or vitreomacular traction.<sup>9</sup> In this patient, OCT revealed the presence of a solid, hyperreflective foveal mass with overlying CME. OCT was also useful in monitoring the resolution of CME and disappearance of the foveal mass.

The rapid disappearance of the foveal mass and CME after corticosteroid treatment strongly suggests that the

lesion was inflammatory in nature. Recurrence of the condition with premature cessation of antiinflammatory treatment added further evidence that an inflammatory process was occurring. We describe this condition as an idiopathic inflammatory foveal granuloma. The absence of concomitant signs of uveitis, such as anterior chamber or vitreous cells, snowbanking, and choroidal nodules, make it difficult to attribute this case to other established common causes of uveitis-induced CME, such as anterior uveitis, pars planitis, or ocular sarcoidosis. The rapid return of normal vision after treatment suggests that this is a relatively benign condition. In this case, OCT provided a noninvasive means of identifying the intraretinal pathologic processes and pointed to a treatment strategy. The value of performing OCT in the management of CME is clearly demonstrated in this case report.

#### References

1. Gass JDM, Anderson DR, Davis EB. A clinical, fluorescein angiographic, and electron microscopic correlation of cystoid macular edema. *Am J Ophthalmol* 1985; 100: 82-86.
2. Fine BS, Brucker AJ. Macular edema and cystoid macular edema. *Am J Ophthalmol* 1981; 92: 466-481.
3. Wolter JR. The histopathology of cystoid macular edema. *Graefes Arch Clin Exp Ophthalmol* 1981; 216: 85-101.
4. Tso MOM. Pathology of cystoid macular edema. *Ophthalmology* 1982; 89: 902-915.
5. Nussenblatt RB, Kaufman SC, Palestine AG, et al. Macular thickening and visual acuity: measurement in patients with cystoid macular edema. *Ophthalmology* 1987; 94: 1134-1139.
6. Nussenblatt RB, Palestine AG, Chan CC, et al. Randomized, double-masked study of cyclosporine compared to prednisolone in the treatment of endogenous uveitis. *Am J Ophthalmol* 1991; 112: 138-146.
7. Dick JSB II, Jampol LM, Haller JA. Macular edema. In: Ryan SJ, ed. *Retina*, 3rd ed. St. Louis, MO: Mosby; 2001 :967-981.
8. Hee MR, Puliafito CA, Wong C, et al. Quantitative assessment of macular edema with optical coherence tomography. *Arch Ophthalmol* 1995; 113: 1019-1029.
9. Gallemore RP, Jumper JM, McCuen BW II, et al. Diagnosis of vitreoretinal adhesions in macular disease with optical coherence tomography. *Retina* 2000; 20: 115-120.

## IRVAN Syndrome

Norlina M. Ramli, MBBS, MRCOphth  
Mimiwati Zahari, MBBS, MRCS (Edin)

Department of Ophthalmology  
University Malaya  
Malaysia

### ABSTRACT

#### Objective

To report a case of idiopathic retinal vasculitis and neuroretinitis (IRVAN) syndrome.

#### Methods

This is a case report.

#### Results

A 35-year-old Caucasian male was referred for evaluation of posterior uveitis. Vitritis, retinal vasculitis, and capillary dropout in the peripheral retina were observed. Fluorescein angiography confirmed the changes. Systemic and blood work-up revealed negative findings. Oral steroid combined with a systemic immunosuppressant had no effect on the disease course. The pattern of the disease and lack of response to immunosuppressives were consistent with a diagnosis of IRVAN syndrome. The patient remained on regular follow-up and maintained good visual acuity of 6/6 in the affected eye.

#### Conclusion

Clinicians should be aware of the existence of IRVAN syndrome to prevent injudicious use of steroids and systemic immunosuppressants in these patients.

IDIOPATHIC retinal vasculitis, aneurysms, and neuroretinitis (IRVAN) syndrome is diagnosed after normal systemic work-up and lack of treatment response to immunosuppressants.

A 35-year-old Caucasian was referred by his optician for evaluation of posterior uveitis. The patient experienced "cloudy" vision in his right eye for a few years, not severe enough to seek consultation. Otherwise, he was healthy. Systemic evaluation revealed no history of bowel, respiratory, or skin disorders. He had not travelled recently to the tropics, did not smoke, and had no family history of eye or systemic disease.

On examination, best-corrected visual acuity was 6/6 OU (OD: -1.25/+2.25 x 85; OS: -4.75/+0.50 x 80). Pupillary reactions, intraocular pressure (IOP), and color vision were normal in the right eye. Anterior-segment examination of the left eye revealed mid-peripheral iris transillumination defects, Krukenberg spindle, darkly pigmented trabecular meshwork, and IOP of 24 mm Hg. These findings were consistent with pigment-dispersion syndrome.

Examination of the right eye also revealed some fine dusting of keratic precipitates. There were 1+ cells in the anterior chamber and anterior vitreous. A mild posterior subcapsular cataract was present. The vitreous was synergetic and peripherally there were preretinal vitreous opacities. Multiple aneurysmal dilatation of the arterioles and hard exudates associated with areas of capillary nonperfusion were noted at the peripheral retina. Fluorescein angiogram (FA) confirmed areas of capillary nonperfusion and aneurysmal dilatation of the arterioles (Figure 1). There was late disc staining, suggestive of neuroretinitis, with leakage from new vessels at the disc.

Extensive uveitis work-up, including ESR, C-reactive protein, antinuclear antibodies, rheumatoid factor, anticardiolipin antibodies, C3, C4, Bartonella antibodies, angiotensin converting enzyme level, fluorescent