

CASE REPORT

Joseph M. Ranche, MD
Raul D. Cruz, MD
Froilan P. Inocencio, MD

*Department of Ophthalmology
and Visual Sciences
University of the Philippines
Philippine General Hospital
Manila, Philippines*

Methanol-induced bilateral optic neuropathy

ABSTRACT

Objective

To emphasize the importance of diagnosing cases of methanol toxicity, demonstrate the value of electrophysiologic testing as an adjunct in the diagnosis, and provide a framework for intervention.

Methods

This is a case report.

Results

The patient's visual-evoked-response tracing showed failure of transmission while electroretinogram waveforms were normal. The findings were consistent with bilateral optic neuropathy from ingestion of methanol.

Conclusion

Complete clinical history and ophthalmologic examination are vital to the diagnosis of methanol toxicity. Respiratory assessment and support and treatment of acidosis are the cornerstone of its management. Currently, the primary therapeutic approach is the use of competitive inhibitors of alcohol dehydrogenase.

Keywords: *Methanol toxicity, Methanol-induced optic neuropathy, Alcohol-related ocular toxicity*

Correspondence to
Joseph M. Ranche, MD
Department of Ophthalmology and Visual Sciences
University of the Philippines
Philippine General Hospital
Taft Avenue, Ermita
1000 Manila, Philippines
Tel: +63-2-5218450 ext. 2178
E-mail: joranmd@yahoo.com

The authors have no proprietary or financial interest in any product used or cited in this study.

LAMBANOG, a local liquor manufactured from coconut, is common in many areas in the Philippines. There have been anecdotal reports of alcohol-induced blindness (popularly referred to as *gin bulag*) in community health centers and provincial hospitals attributed to intake of *lambanog* that had been laced with methanol to enrich its alcohol strength. To our knowledge, such cases have never been reported in local scientific literature.

We report a case of a 72-year-old female with methanol-induced blindness to:

1. emphasize the importance of a thorough clinical history and physical examination in the diagnosis of methanol toxicity,
2. review the significant findings in methanol toxicity,
3. illustrate the current pathophysiologic concepts in methanol toxicity, and
4. outline current and potential areas of intervention and study in the treatment of methanol toxicity.

CASE HISTORY

A 72-year-old female, regular alcohol drinker, consulted at the General Clinic of the Department of Ophthalmology, University of the Philippines-Philippine General Hospital (UP-PGH) after becoming blind following intake of locally manufactured *lambanog*.

Seventeen days prior to consultation, the patient and six other female relatives drank *lambanog*. She consumed about 1 liter of the liquor over a 9-hour drinking session. The next day, she experienced sudden clouding of vision with associated headache, nausea, and abdominal discomfort. Three days later, she became blind.

Medical and family history was unremarkable. Initial examination revealed vital signs within normal limits (BP 120/80; HR 78; RR 20). Patient had no light perception in both eyes (OU). Pupils were dilated at 5 mm and nonreactive to light. Intraocular pressures were normal. There was a 2+ nuclear sclerosis with posterior subcapsular cataract OU. Dilated fundoscopic examination showed distinct disc borders with generalized disc pallor, a cup-disc ratio of 0.3 OU, an artery-to-vein caliber ratio of 2:3. No hemorrhages or exudates were seen. The rest of the neurologic examination was normal.

Optic neuropathy secondary to methanol toxicity was considered.

Further work-up included chromatographic analysis of the liquor sample, which revealed the presence of methanol. Visual-evoked response (VER) showed failure of optic-nerve conduction while electroretinogram (ERG) was normal. Cranial computed tomography (CT) showed physiologic calcifications in the basal ganglia, particularly in the area of the lentiform nucleus.

DISCUSSION

Methanol (CH₃OH, wood alcohol) is a common additive solvent in fuel, windshield washing fluids, photocopying fluids, and paint removers. It has also been used as an adulterant to bootleg liquor.^{1,2} Ingestion of liquor has been implicated in methanol toxicity as early as 1904, with the publication of Wood and Buller's report on 153 cases of blindness caused by methyl alcohol poisoning.³ A major catastrophe in 1951 documented 323 cases of methanol toxicity after intake of bootleg whiskey containing 35-40% methanol, later published as a comprehensive study by Benton and Calhoun in 1953. Most recent was a case in December 2000 of a Finn developing visual deterioration resulting in monocular blindness (counting fingers in the left eye) following ingestion of locally produced coconut liquor in Indonesia.⁴ Halavaraa et al. reiterated the importance of history-taking and the presence of neuro-ophthalmologic findings as central in the diagnosis of methanol toxicity.⁴ A high index of suspicion to the possibility of toxic alcohol ingestion in the setting of ethanol intoxication is important as methanol toxicity may mimic ethanol intoxication early on.^{4,5,6}

Our patient presented initially with nausea, vomiting, and central-nervous-system (CNS) depression, symptoms that are nonspecific and may be attributed to the direct toxic effects of methanol.^{1,7} She experienced blurring of vision 18 hours after ingesting the poison. This is explained by the lag time needed for the body to metabolize the poison to formic acid, an inhibitor of mitochondrial cytochrome oxidase that causes metabolic acidosis and tissue injury.^{1,7,8}

Human and animal models of methanol ocular toxicity have shown particular vulnerability of the optic nerve and the retina;^{9,10,11,12,13,14} the mechanism of injury, however, remains obscure. It has been theorized that this may be due to:

1. the differentially larger oxygen demand in these structures (Zitting et al. 1982, as cited by Liesivuori J & Savolainen H. 1991),⁸
2. low cytochrome-oxidase activity combined with selective accumulation of formate in the said structures,⁹ or
3. differential mitochondrial uptake.¹⁴

It is generally accepted that the final common pathway for nerve or retinal damage is mitochondrial toxicity caused by the metabolite formic acid.^{8,9,14}

Initial fundus findings reveal optic-disc hyperemia or edema with associated blurring of vision resulting from mitochondrial disruption, leading to histotoxic anoxia. If uncorrected, this can progress to cell death observed as pseudoglaucomatous changes or optic atrophy^{4,6,8,10} as seen in our patient. Optic-nerve and retinal pathology manifests as attenuation or loss of VER or ERG waveforms.

Our patient presented with loss of VER waveforms (Figure 1), and normal ERG (Figure 2), indicating the damaging effect of formic acid was solely in the optic nerve.

Loss of mitochondrial function and the ensuing metabolic acidosis also predisposes certain areas of the brain to hemorrhage, necrosis, and calcifications, owing to disrupted membrane integrity.^{8,9,14} These pathologic changes as seen in T2 weighted images via gradient spin echo technique are helpful in the diagnosis of methanol toxicity.⁴

A framework (Figure 3) for understanding the patho-physiologic mechanism of methanol-induced injury is presented.^{8,9,14} Methanol may exert its effect on the CNS as a direct depressant. Approximately 90% of methanol is metabolized by alcohol dehydrogenase to formaldehyde. This is the rate-limiting step in methanol metabolism following first order kinetics at small concentrations, eventually reaching saturation and a shift to zero order kinetics at methanol levels of 20mg/dL. Formaldehyde is further oxidized to formic acid, the toxic metabolite of methanol.

Formic acid is eliminated by the body through its entrance in the one carbon unit transfer utilizing folate as a co-factor. Formate combines with tetrahydrofolate through formyl-THF synthetase to form 10-formyl-THE, which undergoes further oxidation to create CO₂ and H₂O. Alcoholics have been documented to have lower levels of folate, which may predispose them to the damaging effects of formate owing to its slower metabolism.

Formate does damage in a milieu of high-anion-gap metabolic acidosis (HAGMA). More importantly, it is a direct inhibitor of the mitochondrial cytochrome oxidase, thereby disrupting the oxidative process occurring in the respiratory chain. This leads to anoxia, which is more pronounced in areas of high ATP dependence like the optic nerve and retina. Anoxia leads to membrane disruption leading to the morphologic changes noted on the level of the mitochondria. Acidosis aggravates these as protons increase the production of membrane-damaging reactive oxygen species as well as the influx of Ca⁺⁺ through membranes.

Based on the pathophysiology of methanol toxicity, there are several approaches to treatment (Figure 3).^{1,8,9,14,15,16} The cornerstone of poisoning management is respiratory assessment and support, and the treatment of acidosis. The presence of formate has been shown to correlate with findings indicative of HAGMA and decreased serum bicarbonate.

Currently, the primary therapeutic approach is the use of competitive inhibitors of alcohol dehydrogenase (ADH). Intravenous or oral ethanol has long been utilized

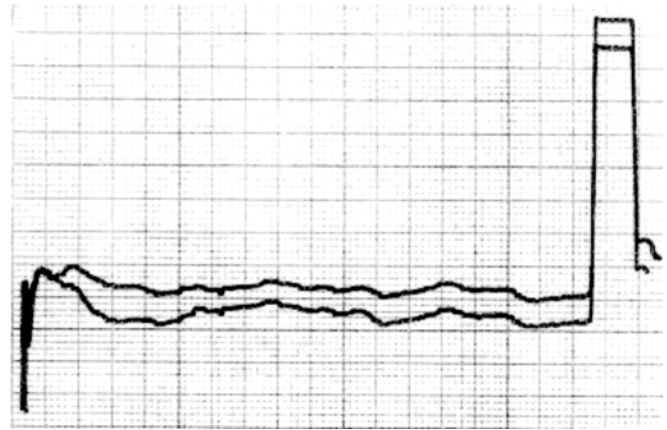


Figure 1. Visual-evoked-response tracing.

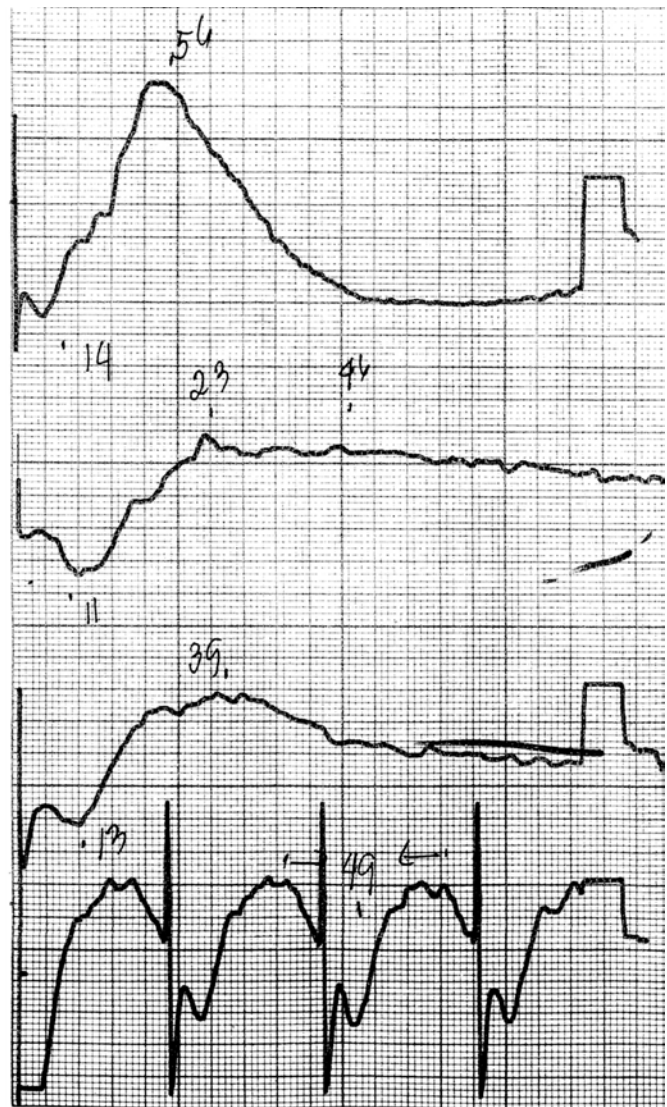


Figure 2. Representative electroretinogram tracings.

because of its greater affinity for ADH than methanol. It blocks formate production, allowing the respiratory and renal routes of excretion of methanol to set in. Recently, an alternative inhibitor 4-methyl pyrazole (Fomepizole, Antizole, Orphan Medical, Minnetonka, MN, USA) has clinically been shown to be effective in the treatment of methanol poisoning.¹⁶

Other approaches to management of acute intoxication are:^{1, 14, 15}

1. Hemodialysis to enhance methanol elimination. There are conflicting findings on the role of dialysis in formate elimination.¹

2. Bicarbonate treatment to counter metabolic acidosis.

3. Treatment with folic acid or folinic acid to counter the metabolism of formate.

Other approaches undergoing animal studies are:^{13, 14, 15}

1. Photobiomodulation using red to near-infrared wavelengths to upregulate cytochrome oxidase, thereby overcoming the inhibition by formate. Photobiomodulation using light-emitting diode may provide a cheap alternative in methanol toxicity and retinal and optic-nerve conditions where the final common pathway lies in the inhibition of cytochrome or disruption in the respiratory chain.¹⁴

2. Use of antioxidants as adjunct in treatment. They act as scavengers of oxygen radicals created by the proton-rich milieu.

2. Davis LE, Hudson O, Benson BE, et al. Methanol poisoning exposures in the United States: 1993-1998. *Clin Toxicol* 2002; 40: 499-505.
3. Hayreh MS, Hayreh SS, Baumbach GL, et al. Methyl alcohol poisoning: ocular toxicity. *Arch Ophthalmol* 1977; 95: 1851-1858.
4. Halavaraa J, Valanne L, Setälä K. Neuroimaging supports the clinical diagnosis of methanol poisoning. *Neuroradiology* 2002; 44:924-928.
5. Weinberg L, Stewart J, Wyatt JP, et al. Unexplained drowsiness and progressive visual loss: methanol poisoning diagnosed at autopsy. *Emerg Med* 2003; 15: 97-99.
6. Cursiefe C, Bergua A. Acute bilateral blindness caused by accidental methanol intoxication during fire "eating". *Br J Ophthalmol* 2002; 86: 1064-1065.
7. Kerns W II, Tomaszewski C, McMartin K, et al. Formate kinetics in methanol poisoning. *Clin Toxicol* 2002; 40: 137-143.
8. Liesivuori J, Savolainen H. Methanol and formic acid toxicity: biochemical mechanisms. *Pharmacol Toxicol* 1991; 69: 157-163.
9. Martin-Amat G, Trepheyl TR, McMartin KE, et al. Methyl alcohol poisoning, development of a model for ocular toxicity using the rhesus monkey. *Arch Ophthalmol* 1977; 95:847-850.
10. Baumbach GL, Cancilla PA, Martin-Amat G, et al. Methyl alcohol poisoning, alterations of the morphological findings of the retina and optic nerve. *Arch Ophthalmol* 1977; 95: 1859-1865.
11. Mbia JE, Guerit JM, Haufrond V, Hantson P. Fomepizole therapy for reversal of visual impairment after methanol poisoning: a case documented by visual-evoked-potential investigation. *Am J Ophthalmol* 2002; 134: 914-916.
12. Plaziac C, Lachapelle P, Camanova C. Effects of methanol on the retinal function of juvenile rates. *Neurotoxicology* 2003; 24: 255-260.
13. Seme MT, Summerfelt P, Nietz J, et al. Differential recovery of retinal function after mitochondrial inhibition by methanol intoxication. *Invest Ophthalmol Vis Sci* 2001; 42: 834-841.
14. Treichel JL, Henry MM, Shumutz CMB, et al. Formate, the toxic metabolite of methanol, in cultured ocular cells. *Neurotoxicology* 2003; 24: 825-834.
15. Eells JT, Henry MM, Summerfelt P, et al. Therapeutic photobiomodulation for methanol-induced retinal toxicity. *Proc Natl Acad Sci U S A* 2003; 100: 3439-3444.
16. Brent J, McMartin K, Philips S, et al. Fomepizole for the treatment of methanol poisoning. *N Engl J Med* 2001; 344: 424-429.

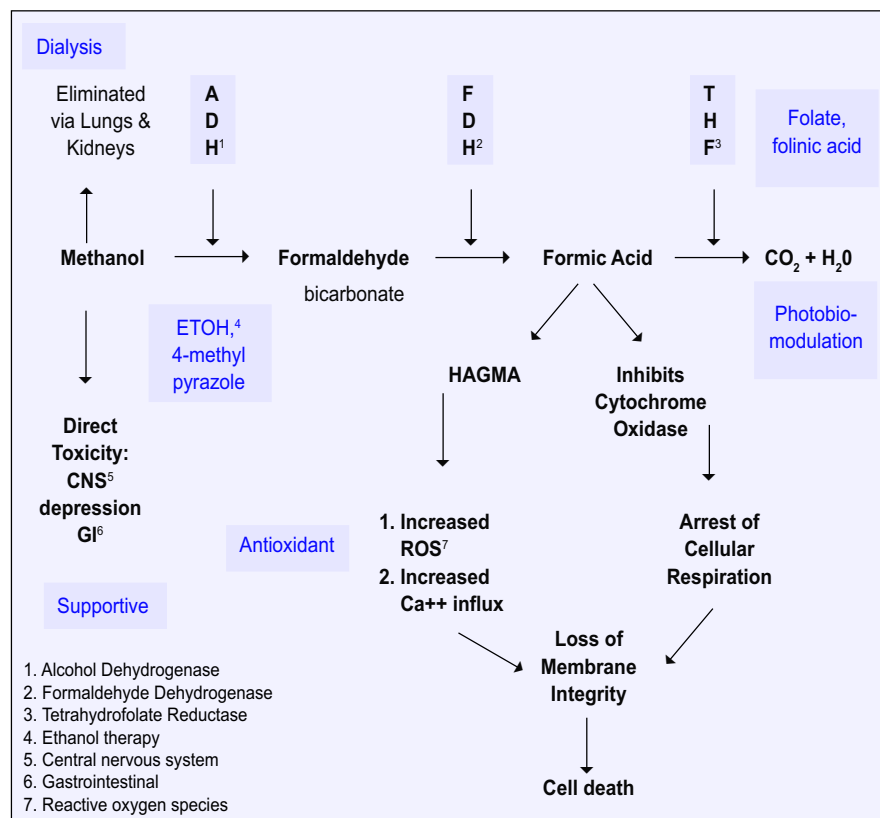


Figure 4. Pathophysiology of methanol toxicity showing sites of potential interventions.

References

1. Dyer S. Methanol Update. *Clinical Toxicology Review* 1998; <http://www.maripoissoncenter.com/ctrl/9802methanol.html> (accessed May 2004).