

PHILIPPINE JOURNAL OF Ophthalmology



A PUBLICATION OF THE PHILIPPINE ACADEMY OF OPHTHALMOLOGY • FOUNDED IN 1969

VOL. 30 No. 1 • JANUARY - MARCH 2005



The pressor and mydriatic effects of tropicamide and phenylephrine
Muller-muscle recession for mild to moderate upper-eyelid retraction
Retinal toxicity of moxifloxacin injected intravitreally into rabbit eyes
Bonding strengths of 2-Octyl cyanoacrylate, N-butyl-2-cyanoacrylate, and nylon 10-0
Axial-length computation using corneal dimensions and A-scan biometry
Preseptal and orbital cellulitis at the Philippine General Hospital
Pupil-size measurement with a digital camera
Patterns of uveitis in a Philippine eye clinic



Opening Eyes, Uplifting Lives

PHISSN0031-7659
PAPI Cert. No. 291

EDITOR IN CHIEF

Patricia M. Khu, MD, MSc

ASSOCIATE EDITORS

Romulo N. Aguilar, MD, PhD
Marissa N. Valbuena, MD, MHPEd

ASSISTANT EDITORS

Jessica Marie R. Abaño, MD
Ruben Lim Bon Siong, MD
Santiago A.B. Sibayan, MD, PhD
Jocelyn L. Sy, MD
Joseph Anthony J. Tumbocon, MD
Harvey S. Uy, MD

MANAGING EDITOR

Carlos G. Naval, MD

EDITORIAL BOARD

Romeo V. Fajardo, MD
FOUNDING EDITOR, PHILIPPINES

Romeo B. Espiritu, MD
PHILIPPINES

Salvador R. Salceda, MD
PHILIPPINES

Rossina Lydia A. Ramirez, MD, MHSc
PHILIPPINES

Roger W. Beuermann, PhD
SINGAPORE/USA

Donald Tan, MD, FRCS
SINGAPORE



The PHILIPPINE JOURNAL OF OPHTHALMOLOGY (PJO), the official journal of the Philippine Academy of Ophthalmology, aims to provide a venue for exchange of ideas and information among ophthalmologists and other physicians. It publishes peer-reviewed reports of original clinical and laboratory investigations, epidemiological studies done in the Philippines and other countries, major reviews of specific topics, evaluation of diagnostic and surgical techniques, treatment methods, latest updates, and controversial issues in ophthalmology.

Published quarterly, Number One of Volume One is dated January–March 1969. Entered as a third-class mail matter at the Manila Post Office on February 13, 1969. Journal International Standard Serial Number: PHISSN 0031 - 7659. Vol. 29 No.1, March 2004.

Copyright 2004. All rights reserved.



Philippine Academy of Ophthalmology
Unit 815 Medical Plaza Makati
Amorsolo Street, corner De la Rosa Street
1229 Makati City, Philippines
Telephone +63-2-8135324
Fax: +63-2-8135331
Email: pjo@pao.org.ph

Publishing and Editorial Consultants



5/F King's Court II
2129 Chino Roces Avenue
1231 Makati City, Philippines
Tel. Nos. +63-2-8112206 to 10 • Fax +63-2-8112182
Email: edit@medobserver.com

NOTICE TO READERS AND CONTRIBUTORS

SUBMISSION

Manuscripts should be submitted to the editorial offices of the PHILIPPINE JOURNAL OF OPHTHALMOLOGY (PJO) at the Philippine Academy of Ophthalmology (PAO), Unit 815 Medical Plaza Makati, Amorsolo Street, corner Dela Rosa Street, 1229 Makati City, Philippines.

Authors must submit, along with the manuscript, a duly accomplished and signed copyright transfer. No manuscript will be reviewed until the signed copyright transfer is received.

The author/s shall pay for the cost of the color separation processing for color photographs included in the manuscript.

Manuscripts submitted for consideration are reviewed by editors and other experts in the field. Reviewers are consultants to the editor and are instructed not to discuss the paper with the authors. Reviewers should not cite the manuscript or refer to the work it describes before it has been published. Reviewers should refrain from using the information contained in the manuscript for the advancement of their own work or that of their colleague or institution.

SUBSCRIPTION

The Journal is published quarterly; subscribers will receive four issues per year with supplements on special topics that the editors deem of interest or significance. PAO members in good standing are automatically enrolled subscribers with no additional fees except for the supplements. Nonmembers may subscribe at the following rates, which include delivery fees and online access to the PJO website.

Individual

Local	PhP	1,200.00
Foreign	USD	70.00

Institutional

Local	PhP	1,400.00
Foreign	USD	90.00

Particular issues may be purchased at the following rates per copy subject to availability:

Individual

Local	PhP	350.00
Foreign	USD	20.00

Institutional

Local	PhP	450.00
Foreign	USD	25.00

DISCLAIMER

Statements and opinions expressed in the articles and communications herein are those of the author(s) and not necessarily those of the Editor(s) or the Publisher (Philippine Academy of Ophthalmology). The Editors and the PAO assume no responsibility for any injury and/or damage to persons or property as a matter of product liability or negligence or which otherwise arise from use or operation of any methods, products, instructions, or ideas cited or discussed in any article in the Journal.

Although all advertising materials are expected to conform to ethical (medical) standards, the appearance of advertising in PJO does not constitute a guarantee or endorsement by the PJO or the PAO of the quality or value of such product or the claims made for it by its manufacturer.

REPRINTS/ ADVERTISING

Reprint requests and advertising inquiries may be addressed to the Managing Editor, PHILIPPINE JOURNAL OF OPHTHALMOLOGY, Unit 815 Medical Plaza Makati, Amorsolo St., corner Dela Rosa St., 1229 Makati City, Philippines.



**The PHILIPPINE
ACADEMY of
OPHTHALMOLOGY**
National Organization of Filipino Eye MDs



MARCELINO D. BANZON, M.D.
President
Philippine Academy
of Ophthalmology



MA. DOMINGA B. PADILLA, M.D.
Organizing Committee Chair
2005 Joint PAO-AAO
Meeting in Manila

It is with pleasure that we invite all of you to Manila for a Joint Meeting of the Philippine Academy of Ophthalmology and the American Academy of Ophthalmology. This historical event will culminate the diamond anniversary celebration of our Academy, a fitting finale for a year that marks 6 decades of service and the pursuit of excellence. This event will gather a distinguished group of faculty from the world over in a setting where various cultures and experiences should blend for a truly exciting meeting. The organizing committee has prepared a four-day program that will have something interesting for all students of Ophthalmology, from the beginning resident to the seasoned practitioner. So please do mark these important dates in your calendar and plan to join us in historic Manila. Enjoy her unique charm, the food, the shopping, the warmth of our people, and a meeting to remember.

Mabuhay!

On behalf of the American Academy of Ophthalmology and its board members, I extend our congratulations to the Philippine Academy of Ophthalmology on the occasion of its 60th Year Diamond Anniversary Celebration.

We are honored to be a partner with the Philippine Academy in commemorating this significant event.



H. DUNBAR HOSKINS, JR., M.D.
Executive Vice President
American Academy
of Ophthalmology

FACULTY

INTERNATIONAL

USA

Richard Abbott
Anthony Arnold
Dimitri Azar
Jorge Camara
Guillermo de Venecia
Donald Fletcher
Robert Kersten
Jemshed Khan
Gregg Kokame
Andrew Lee
Leonard Levin
Samuel Masket
Robert Nussenblatt
David Plager
Steven Scallhorn
Susan Senft
Robert Stampler
Richard R. Tamesis
Scheffer Tseng
Robert Weinreb

SINGAPORE

Shantha Amrith
Ashok Grover
Adrian Koh

Seeh Lay Leng
Chee Soon Phaik
Gangadhara Sundar
Donald Tan
Choo Chai Teck
Doric Wong
Edmund Wong

AUSTRALIA

Andrew Chang
Jill Keefe
Richard le Mesurier

INDIA

Millind Naik
G. Natchiar
Shayam Prasad

HONG KONG

George Woo
Hunter Yuen

JAPAN

Takayuki Akahoshi
Yasuhisa Nakamura

KOREA

Yoon Duck Kim
Sang Yeul Lee

SPAIN

Gonzalo Blanco
Maria Antonia Saornil

UNITED KINGDOM

Allen Foster
Richard Wormald

CANADA

Garth Taylor

ITALY

Paolo Lanzetta

MALAYSIA

Kasturi Batacharjee

PAKISTAN

Hasan Minto

LOCAL

Ma. Rebecca P. Abes
Romulo Aguilar
Manuel B. Agulto
Evelyn Ambrosio
Robert Edward Ang
Mario V. Aquino
Norman Aquino
Reuben Aquino
Jack Arroyo
Milagros Arroyo
Benjamin Cabrera
Teresita R. Castillo
Ildefonso Chan
Sidney Cheng
Raul Cruz
Rolando Enrique Domingo
Jose Luis de Graño
Alejandro S. de Leon
Heriberto Guballa
Raoul Henson
Froilan Inocencio
Reynaldo Javate
Richard Kho
Patricia Khu
Jacqueline H. King

Edgar Leuenberger
Ruben Lim Bon Siong
Victor Lopez
Leonardo Mangubat
Gary Mercado
Ma. Dominga B. Padilla
Catherine Qui-Macaraeg
Alexander Reyes
Johann M. Reyes
Yasmyne Ronquillo
Shiela Santos-Jimenez
Antonio Say
Santiago A. B. Sibayan
Alex Sua
Jesus Tamesis
Pearl Tamesis - Villalon
J. Anthony J. Tumbocon
Harvey Uy
Mario Valenton
Mario Yatco



EDITORIAL

4 PAO: Mission accomplished, vision fulfilled

Dr. Salvador Salceda recalls 60 years of organized Ophthalmology in the Philippines, as the Philippine Academy of Ophthalmology (PAO) marks the occasion. It is, he says, "a time for reexamination of roles and reflection on responsibilities in light of a great medical paradox—that the many who are poor and disadvantaged continue to be strangers to the great progress in ophthalmic science and technology."

ORIGINAL ARTICLES

7 The pressor and mydriatic effects of tropicamide-phenylephrine combination, plain tropicamide, and plain phenylephrine: a randomized, controlled trial
M A Mesina-Bayana, MD
M H Arroyo, MD

20 Bonding strengths of 2-octyl cyanoacrylate, N-butyl-2-cyanoacrylate, and nylon 10-0 in experimental corneal perforations in porcine eyes
J R Elises, MD
L DP Cubillan, MD

34 Estimation of pupil size using a digital camera
A L Zapanta Jr., MD, et al.

37 Patterns of uveitis in a Philippine eye clinic
H S Uy, MD
I W Tam, OD

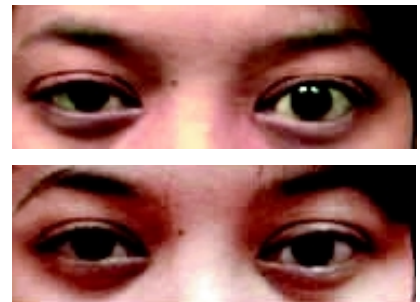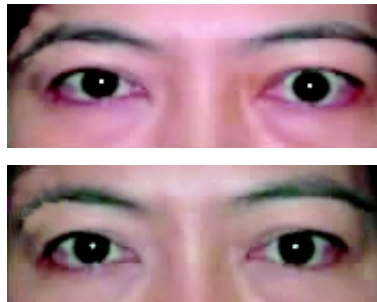
ORIGINAL ARTICLE

12

Muller-muscle recession for mild to moderate upper-eyelid retraction

V B Lopez, MD
M E T Concepcion, MD

Muller-muscle recession is an effective means of relieving mild to moderate upper-eyelid retraction in patients with Graves' ophthalmopathy before fibrosis sets in.

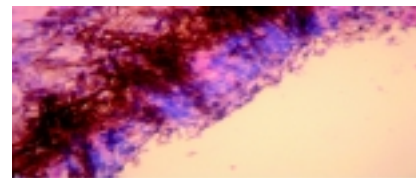


ORIGINAL ARTICLE

17

Retinal toxicity of moxifloxacin injected intravitreally into rabbit eyes

L J G Domalanta, MD, et al.
Intravitreal injection of 480 µg or less of moxifloxacin does not produce retinal toxicity histologically in rabbit eyes.

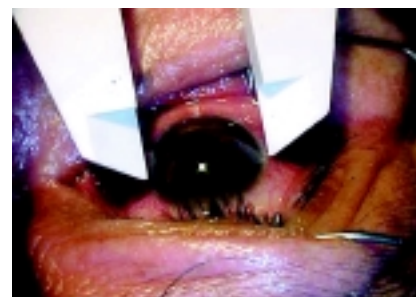

ORIGINAL ARTICLE

24

Axial-length computation using corneal dimensions and A-scan biometry: a comparison

R Matanguihan, MD, et al.
Axial length measured with an A-scan can be reliably approximated by using Surrell's formula based on corneal length measurements.



ORIGINAL ARTICLE

28

Preseptal and orbital cellulitis at the Philippine General Hospital

H S Uy, MD
P M C Tuaño, MD

Orbital cellulitis is associated with greater mortality and morbidity. CT scan and microbial studies are invaluable for appropriate diagnosis and management of orbital cellulitis.

EDITORIAL

60 years of organized ophthalmology

Mission accomplished, vision fulfilled

The celebration can be a time for reexamination of roles and reflection on responsibilities in light of a great medical paradox—that the many who are poor and disadvantaged continue to be strangers to the great progress in ophthalmic science and technology.

THE PHILIPPINE Academy of Ophthalmology (PAO) is celebrating the 60th anniversary of organized Ophthalmology in the country. The occasion provides Filipino eye physicians and the public many opportunities. It is a time, as planned, for socially relevant activities that accrue to the understanding, appreciation, and possession of functionally useful eyes.

The celebration can be a time for reexamination of roles and reflection on responsibilities in light of a great medical paradox—that the many who are poor and disadvantaged continue to be strangers to the great progress in ophthalmic science and technology.

Finally, the occasion may be a time of remembrances of the early beginnings of the medical specialty and of its Filipino pioneers in the country.

Importance of sight

Sight is important. As much as 80 percent of our learning and work processes are performed with the help of sight. Along with the other four senses—touch, taste, smell, and hearing—sight is our window to the empirical world. Through these senses, we are inextricably bound to what is outside of us. And if reality is what we experience, the visual images we construct, store in, and retrieve from our “memory bank” contribute to the pool that is our total experience. These images link us to our past, anchor us to our present, and perhaps provide us glimpses of our future.

The eye is our organ of sight. It is like a spherical camera consisting of a focusing lens system and a film that captures to the last and finest detail that which comes to us via the visible light. It has evolved through millions of years, from a simple dot of pigment on the surface

skin of the simplest invertebrates to the pair of globes that became, for the first time, frontally placed in the heads of our simian ancestors. There, side by side in perfect partnership, they give us a field of vision with breadth and depth as if to admonish us to be comprehensive and profound. And through some mysterious ways science has yet to fully unravel, we see our world not in the drabness of white and black, of light and shadows, but in the lushness of colors that along with form, aesthetics and visual art use as powerful tools to express and to arouse human emotions.

Our eyes have served and continue to serve us well. From our first conscious act to cease being a mere figure in the horizon to our willful acts of shaping that horizon, we rely on our eyes. From the more mundane concerns required by our daily lives to survive to our ennobling and edifying achievements, we use our eyes. Verbal thought has its uses. But it is imperfect, language itself is inadequate. Indeed, a picture is worth a thousand words, a wise man said.

Brief history

Ophthalmology came to the Philippines early. It was taught in the medical school of the *University of Santo Tomas* (UST) in 1871. An eye dispensary was opened in *San Juan de Dios Hospital* in 1906.

No less than Dr. Jose P. Rizal, after his training in Europe, practiced the specialty in the Philippines from 1887 to 1896.

America may have introduced the EENT tradition in the Philippines, but it was supportive of the development of Ophthalmology in the country. With increasing opportunities for training in the USA, complementing those in Europe, many Filipino physicians pursued Ophthalmology as a specialty. The return of these new specialists presaged the creation of the Eye Departments, which were crucial instrumentalities for the teaching. These and the organization of the eye societies, the institutionalization of the capacity for scientific

Correspondence to
Salvador R. Salceda, MD
Professor Emeritus, Ophthalmology
University of the Philippines Manila
Pedro Gil Street, Ermita
1000 Manila, Philippines
Tel.: +63-2-5264170

research, the scientific journals, eye banks, blindness prevention societies, and others contributed to the formative and consolidation stages of the specialty.

The development of Ophthalmology as a separate specialty in the Philippines was Dr. Geminiano de Ocampo's apostolate. Weaning Ophthalmology from Otolaryngology at a time the EENT tradition was already firmly institutionalized in the teaching institutions and by professional specialty society was not easy and would take more than a decade to achieve.

The 1950s were propitious years for Ophthalmology. The Philippine Eye Bank for Sight Restoration was organized in 1951 as mandated by Republic Act No. 349. Dr. de Ocampo established the first eye hospital in Manila in 1952. President Ramon Magsaysay issued Proclamation No. 49 in July 1954, mandating the yearly observance of National Sight Saving Week. In 1958, the National Society for the Prevention of Blindness was organized to take charge of the observance from the Philippine Eye Bank. In September 1958, during the 18th International Congress of Ophthalmology in Brussels, the Asia-Pacific Academy of Ophthalmology was organized with Dr. de Ocampo as its first president. The Academy brought into one organization the eye societies of the member countries in the region. It assigned the Philippines to host the first congress in Manila in 1960.

Even more significant to the growth of Ophthalmology in the Philippines was the creation of eye departments in the medical schools and in their training hospitals. In 1954, the Manila Central University established the first eye department for its medical school and training hospital with Dr. Edgardo Caparas as chairman. In 1961, the eye section of the EENT Department of the PGH, the training hospital of the UP College of Medicine, was formally converted to a separate department by the University's Board of Regents with Dr. Geminiano de Ocampo as the first chairman. The UST Medical School became the third educational institution to have a separate eye department in 1984 with Dr. Cosme Naval as chairman. More would follow. Not only were eye departments created by separating existing EENT departments, but by organizing new ones in medical schools and training hospitals that were later established.

Essential to the growth and development of Ophthalmology is the need for an instrumentality that facilitates the exchange and sharing of knowledge and expertise in the spirit of collegiality and brotherhood.

On November 25, 1945, 24 practicing Filipino EENT physicians gathered at the old North General Hospital

along España Street in Manila and organized the Philippine Ophthalmological and Otolaryngological Society (POOS), the first medical specialty to be formed in the country and officially recognized and affiliated with the Philippine Medical Association. The Society's main goal was to contribute to the growth and development of the specialty. It established an EENT Library; published a journal, the *POOS Bulletin* in 1946 which became the *Philippine Journal of Ophthalmology and Otolaryngology* in 1955; held regular scientific meetings often with foreign specialists; and created a Qualifying Board in 1950, which was reorganized into the Philippine Board of Ophthalmology and Otolaryngology in 1954 to certify to the competency of the practitioners.

By the end of the 1950s, Filipino ophthalmology practitioners considered a separate eye society essential to the growth of the specialty in the country. With the organization of the Asia-Pacific Academy of Ophthalmology in 1958 and the designation of the Philippines as host of the Academy's first congress in Manila in 1960, the decision to establish an eye society became so compelling that Filipino ophthalmologists did create not one but two eye societies: the Philippine Ophthalmological Society (POS) on October 24, 1958 and the Ophthalmological Society of the Philippines (OSP) on November 25, 1958. Each group firmly believed that its society was the true eye society in the country.

With the help of Dr. Conrado Banzon as POOS president, and the selflessness of the incumbent presidents of the OSP and POS, Dr. Manuel Hechanova and Dr. Liborio Mangubat, respectively, these two societies would merge into the Philippine Society of Ophthalmology (PSO) in 1970. A new constitution and by-laws were formulated and ratified with the election of new officers.

The POOS that gave birth to the OSP would transform itself into the Philippine Academy of Ophthalmology and Otolaryngology (PAOO) in 1970 to perform roles complementary to those of the PSO and the Philippine Society of Otolaryngology and Broncho-esophagology in the area of graduate, postgraduate, and continuing education and training.

In 1971, the Society designated the PHILIPPINE JOURNAL OF OPHTHALMOLOGY as its official journal for the scientific works of Filipino ophthalmologists. Starting as the Section of Ophthalmology in the *Philippine Journal of Surgery and Surgical Specialties*, then as the *Transaction of the Philippine Ophthalmological Society*, it finally became the PHILIPPINE JOURNAL OF OPHTHALMOLOGY in 1969 with Dr. Romeo Fajardo as editor in chief.

In 1974, the Society supported the 1966 initiative of

the University of the Philippines-Philippine General Hospital (UP-PGH) Department of Ophthalmology to publish an ophthalmology textbook for medical students and general medical practitioners. Completed in 1980 and authored by Drs. Romeo Fajardo, Romeo Espiritu, and Cosme Naval with a host of other Filipino ophthalmologists, the *Textbook of Ophthalmology* helped standardize the teaching of the specialty in undergraduate medicine.

The PAOO institutionalized the program of graduate, postgraduate, and continuing education in the specialty. It conducted seminars, symposiums, instructional courses, and workshops on selected topics in ophthalmology with Filipino and foreign faculties and experts. It also established the *Jose P. Rizal Memorial Lectureship in Ophthalmology* in 1955 to give recognition to Filipino and foreign ophthalmologists who contribute to the growth and development of the specialty in the Philippines.

The PSO also organized its own lectureship, the *Luis Santos Memorial Lecture*, in 1978, which was given by the outgoing president of the society. In 1971, it created the *Philippine Board of Ophthalmology* with the functions of accrediting ophthalmology residency training programs and certifying through examinations those completing the training. It laid down the appropriate guidelines for eye departments wanting to organize training programs. It also welcomed the initiative of the UP-PGH Department of Ophthalmology to organize the Basic Courses in Ophthalmology and the Seminars on Clinical and Surgical Ophthalmology for all eye residents in the country.

In December 1995, the PAOO and the PSO merged to form the national eye society, the *Philippine Academy of Ophthalmology (PAO)*, an organization distinct from the Philippine Academy of Otolaryngology. This new era was marked by tangible camaraderie among the different officers and members of the Academy that was not seen before. As the Filipino ophthalmologists increased in number and grew ever conscious of their expanding responsibilities, professionally and morally, they committed themselves collectively to help address the problem of eye health and blindness in the country. The commitment took the form of socially oriented projects and activities that address the lack of access to needed eye health-care services among the disadvantaged.

National Blindness Prevention Program

Filipino ophthalmologists have always been prodigious in their work to help address blindness as a public-health problem. With the optometric and civic groups, they conduct public information on eye care and sight preservation. They provide direct ophthalmic and optometric services to indigents and in places where the

government does not have the needed facilities and services. In the past, much of the work on blindness prevention of these organizations were uncoordinated for lack of a common plan. The annual observance of Sight Saving Week and the activities of the National Society for the Prevention of Blindness, at best, increased awareness on the importance of sight but created expectations for needed services that could not be met adequately.

All of these changed with the merger of the two ophthalmologic societies into PAO, whose vision is "that every Filipino will have access to quality and affordable eye care; no Filipino will succumb to preventable blindness." The Academy seeks to influence the formulation and implementation of eye-health policies; to uphold the technical and ethical standards of ophthalmology as a profession; to assume full moral responsibility for the reduction and prevention of remediable blindness; to lead in information dissemination and public education on primary eye care and preventable eye diseases; and to protect and promote the professional needs of its members and to ensure continuing medical education.

The Academy has actively participated over the years in various community projects and missions to different parts of the country in the hope of eradicating blindness from preventable causes and providing quality care in areas where medical assistance is lacking. It upholds the aims of the national prevention of blindness program in reducing blindness prevalence rate from 1.07% to 0.5% with no community or province having a rate greater than 1.0% by the year 2000. It also seeks to reduce the cataract backlog by 50% within 5 years and the prevalence of Vitamin A deficiency to 0.4%.

In 1999, the Asia Pacific Congress of Ophthalmology was held in Manila for the second time with more than 1,000 local and foreign participants. The convention was considered a success with many distinguished foreign and local speakers giving seminars and workshops. This was followed in 2003 by the first PAO-SERI meeting held in collaboration with the Singapore Eye Research Institute, with emphasis on basic and clinical research.

As the Academy moves onward to becoming internationally recognized for its services to fellow countrymen and contributions to world ophthalmology, the upcoming PAO-AAO international meeting in November where "Asia meets America" is sure to bring in many international renowned speakers and foreign delegates alike in a convention guaranteed to meet the minds of the best and provide many fruitful discussions on the problems encountered in ophthalmology.

ORIGINAL ARTICLE

Marion Alva Mesina-Bayana, MD
Milagros H. Arroyo, MD

*Department of Ophthalmology
and Visual Sciences
University of the Philippines
Philippine General Hospital
Manila, Philippines*

The pressor and mydriatic effects of tropicamide-phenylephrine combination, plain tropicamide, and plain phenylephrine

A randomized, controlled trial

ABSTRACT

Objective

To evaluate the pressor and mydriatic effects of different concentrations of tropicamide and phenylephrine eye drops: tropicamide 0.5% (Mydriacyl), phenylephrine hydrochloride 2.5% (Mydfrin), tropicamide-phenylephrine combination 0.5%/0.5% (Sanmyd-P), and self-prepared mixture (1:1 dilution) of commercially prepared tropicamide 0.5% and phenylephrine 2.5%.

Methods

A prospective, randomized, double-blind study was carried out involving 160 eyes of 80 patients who were randomly assigned into four groups to receive phenylephrine + tropicamide 0.5%/0.5% (Group A), tropicamide + phenylephrine 0.2%/1.25 (Group B), tropicamide 0.5% (Group C), or phenylephrine 2.5% (Group D). The main outcome measures were systolic, diastolic, and mean arterial pressures; pulse rate; and horizontal pupillary diameter determined at 10-, 20-, 30-, 45-, and 60-minute intervals postinstillation. Repeated measures analysis of variance and Tukey's honestly significant difference were used to analyze outcomes.

Results

There was no significant increase in the systolic and diastolic blood pressure within each group and between groups. The mean increase or decrease in heart rate from baseline did not show a significant difference. Tropicamide-phenylephrine 0.5%/0.5% (Group A) and tropicamide-phenylephrine 0.25%/1.25% (Group B) yielded the highest mean increase in pupil size across time.

Conclusion

Tropicamide-phenylephrine 0.5%/0.5% and tropicamide-phenylephrine 0.25%/1.25% attained better dilation per unit time than the other treatment groups. No significant effect on blood pressure and heart rate was seen in all groups.

Keywords: *Tropicamide, Phenylephrine, Mydriatic, Blood pressure, Heart rate*

Correspondence to
Marion Alva Mesina-Bayana, MD
Department of Ophthalmology and Visual Sciences
University of the Philippines-Philippine General Hospital
Taft Avenue, Ermita
1000 Manila, Philippines
Telephone: +63-2-5218450 ext. 2174
E-mail: ionmb7@yahoo.com

The authors have no proprietary or financial interest in any product used or cited in this study.

TROPICAMIDE and phenylephrine hydrochloride eye drops are widely used for mydriasis in routine ophthalmoscopic examinations and prior to cataract surgery to achieve maximal pupil dilation.

Phenylephrine hydrochloride, a sympathomimetic agonist, is a strong α_1 -receptor stimulant with little or no beta-receptor effect. Cardiovascular actions of phenylephrine include vasoconstriction of the systemic, pulmonary, and coronary arteries. This leads to reduction in cardiac output and renal, splanchnic, cutaneous, and limb blood flow.¹ Consequently, there is an increase in the systolic and diastolic blood pressure, tachycardia, and reflex bradycardia, side effects that are generally unwanted in the clinic or operating room.

Tropicamide, on the other hand, is a parasympathomimetic antagonist that causes mydriasis and cycloplegia.² It is devoid of vasopressor effect, giving it a clear advantage over phenylephrine.

Although either class of drug used alone will produce adequate mydriasis, experience and studies have shown that the use of both a sympathomimetic drug and a parasympathomimetic drug produces maximal mydriasis that is resistant to intense light stimulation.³ Although topical ophthalmic drops are generally safe to use, they may still reach the systemic circulation and cause unwanted side effects. They are absorbed mainly through the corneal, conjunctival, and the nasal mucosa via the lacrimal system.⁴

Several cases of adverse systemic reactions have been reported following topical application of 10% phenylephrine. Adverse responses include elevated blood pressure, tachycardia, reflex bradycardia, cardiac arrhythmias, and subconjunctival hemorrhage.⁵ Kenawy compared phenylephrine 2.5% and 10% in patients undergoing phacoemulsification. The results showed a 10-percent rise in mean systolic blood pressure in both groups 10 to 20 minutes after administration.⁶ Similar results were seen in a study by Kumar in patients undergoing vitreoretinal surgery.⁷ However, Tang did not find an increase in systemic blood pressure in hypertensive patients dilated with 2.5% phenylephrine and 1% tropicamide.⁴

The alternating instillation of commercially available phenylephrine 2.5% and tropicamide 0.5% given every 5 minutes has become the general practice in the clinic to dilate the pupil. This, however, is time-consuming and inefficient. This study determined if the mixture of commercially prepared phenylephrine and tropicamide is effective and safe. It evaluated the pressor and mydriatic effects of different concentrations of tropicamide and phenylephrine eye drops: tropicamide 0.5% (Mydriacyl, Alcon-Couvreur, Puurs, Belgium), phenylephrine hydrochloride 2.5% (Mydfrin, Alcon Laboratories, Fort Worth, TX, USA), tropicamide-phenylephrine combination

0.5%/0.5% (Sanmyd-P, Santen Pharmaceutical, Osaka, Japan), and self-prepared mixture (1:1 dilution) of commercially prepared tropicamide 0.5% and phenylephrine 2.5%.

METHODOLOGY

This is a prospective, double-blind, randomized, controlled trial involving 160 eyes of 80 patients, 20 to 70 years old, scheduled for preoperative cataract evaluation at the outpatient ophthalmology clinic of the University of the Philippines-Philippine General Hospital. Excluded from the study were patients with tearing, history of use of any eye drops within the previous two weeks, contact lens wear, ocular surgery, trauma, and systemic diseases (e.g. diabetes mellitus, hypertension, arthritis, thyroid disease). Patients with afferent pupillary defect (RAPD), irregular pupil, corneal pathology, uveitis, and glaucoma were also excluded.

The following ophthalmologic examinations were done in each case: visual acuity determination, test for RAPD, Schirmer's test, direct funduscopy, applanation tonometry, and slit-lamp biomicroscopy to determine anterior chamber depth by the Van Herick method. Baseline blood pressure, heart rate, and pupillary diameter were measured prior to instillation of mydriatic eye drops.

Commercially available tropicamide 0.5% drops (Mydriacyl, Alcon-Couvreur, Puurs, Belgium), phenylephrine hydrochloride 2.5% drops (Mydfrin, Alcon Laboratories, Fort Worth, TX, USA) and tropicamide-phenylephrine 0.5%/0.5% drops (Sanmyd-P, Santen Pharmaceutical, Osaka, Japan) were used for the study. The eye drops were transferred by a research assistant into four sterile, identical droptainers using aseptic technique and were labeled as A (tropicamide-phenylephrine 0.5%/0.5%), B (tropicamide-phenylephrine 0.25%/1.25%), C (tropicamide 0.5%), and D (phenylephrine 2.5%). Patients were assigned into four groups using blocked randomization. The mydriatic eye drops were administered in a double-masked manner; neither the patient nor the person administering the eye drops knew which solution was given.

Both eyes of each subject received a drop of proparacaine hydrochloride 2%. Three minutes later, two drops of each mydriatic drug was administered on both eyes at five-minute intervals for a total of 3 doses. The drops were instilled into the inferior cul-de-sac of each eye with the patient looking up. The patient was then asked to close the eyes gently and avoid squeezing the eyelids for 3 minutes. Care was taken to ensure that the dropper tip did not touch the subject's eye to avoid contamination.

Blood pressure, heart rate, and pupil diameter were measured at 10, 20, 30, 45, and 60 minutes following the final instillation of drops. Blood pressure was measured in the right arm, sitting position, using a standard mercur-

rial sphygmomanometer. The horizontal pupillary diameter was measured to the nearest 0.5 mm using a standard millimeter ruler and a loupe (Neitz, 4x) for magnification. The ruler was placed transversely at the midlevel of the pupil. Testing was done in a dimly lit room, with illumination from a fully charged direct ophthalmoscope with its rheostat at half maximum, kept at a distance of 0.5 meter and 15 degrees above the horizontal plane, while the subject fixated on a distant object.⁸ The technician measuring the blood pressure, pulse rate, and pupil size was blinded as to the mydriatic drops used.

Indirect ophthalmoscopy and applanation tonometry were done after 60 minutes. The subjects were told to report any untoward reactions—headache, palpitations, dyspnea, chest discomfort, sweating, and dryness of mouth—as they occur. The data were subjected to repeated measures analysis of variance. Systolic and diastolic blood pressure, pulse rate, and pupillary dilation were analyzed within each drug group and between drug groups. Post hoc analysis was done using Tukey's honestly significant difference. A value of $p < .05$ was required for

the effects on blood pressure, pulse rate, and pupillary dilation to be considered statistically significant.

RESULTS

A total of 180 patients (160 eyes) were enrolled in the study and randomized into four groups of 20 patients each, namely: (A) tropicamide 0.5% + phenylephrine HCl 0.5%, (B) tropicamide 0.25% + phenylephrine HCl 1.25%, (C) tropicamide 0.5% alone, and (D) phenylephrine 2.5% alone.

There was no significant difference in baseline age and sex distribution, vital signs (mean systolic blood pressure, diastolic blood pressure, and heart rate), and predilation pupillary size among the 4 groups (Table 1).

There was no significant increase in systolic blood pressure among the 4 groups from baseline to the 60th minute mark. ANOVA showed a significant decrease in the mean systolic blood pressure from baseline to the 60th minute for all groups ($p = .01$) (Figure 1). Post hoc analysis showed that the systolic blood pressures between the 4 groups varied significantly during the observation period ($p < .05$). There was a large pressure difference of about 10 mm Hg

Table 1. Baseline (predilation) demographic characteristics, blood pressure, and heart rate.

Characteristic	Group A Tropicamide 0.5% + Phenylephrine 0.5% (n=20)	Group B Tropicamide 0.25% + Phenylephrine 1.25% (n=20)	Group C Tropicamide 0.5% (n=20)	Group D Phenylephrine 2.5% (n=20)	p^a
Age (years)					
Range	24 – 69	21 – 75	20 – 71	29 – 65	.11 ^b
Mean	46 ± 9	39 ± 12	45 ± 13	47 ± 9	
Gender					
Male	3	4	6	4	.37
Female	17	16	14	16	
Mean predilation SBP ¹ (mm Hg)	111 ± 12	109 ± 15	111 ± 13	116 ± 13	.30 ^b
Mean predilation DBP ² (mm Hg)	72 ± 8	72 ± 10	71 ± 9	76 ± 8	.24 ^b
Mean predilation HR ³	72 ± 11	74 ± 8	70 ± 6	74 ± 6	.24 ^b
Mean pupil size (OD) (mm)	2.9 ± 0.5	3.1 ± .34	2.8 ± .3	2.8 ± .3	.34 ^b
Mean pupil size (OS) (mm)	2.9 ± 0.5	3.1 ± .34	2.8 ± .3	2.8 ± .3	.34 ^b

1. systolic blood pressure
2. diastolic blood pressure
3. heart rate

- a. significant if $< .05$
- b. computed using One-way ANOVA SPSS Ver. 11

Table 2. Post hoc comparison of the significant mean difference in mydriatic effects among the four drugs across time.

Drug Comparison	Mean Difference (mm)	p^a	95% C.I.
Tropicamide-phenylephrine 0.5%/0.5% v. tropicamide-phenylephrine 0.25% / 1.25% (A v. B)	-.15	.77	-.56 - .26
Tropicamide-phenylephrine 0.5%/0.5% v. tropicamide 0.5% (A v. C)	.45	.02 ^b	.04 - .86
Tropicamide-phenylephrine 0.5%/0.5% v. phenylephrine 2.5% (A v. D)	.87	<.05 ^b	.46 - 1.20
Tropicamide-phenylephrine 0.25%/1.25% v. tropicamide 0.5% (B v. C)	.60	.001 ^b	.19 - 1.10
Tropicamide-phenylephrine 0.25%/1.25% v. phenylephrine 2.5% (B v. D)	1.02	<.05 ^b	.61 - 1.40
Tropicamide 0.5% v. phenylephrine 2.5% (C v. D)	.41	<.05 ^b	.01 - .83

- a. significant if $< .05$
- b. computed using repeated measures ANOVA

between Group B and Group D ($p = .035$), with the latter causing a gradual decrease especially noted at 10, 20, and 30 minutes from administration.

No significant difference was seen in the diastolic blood pressures within each group ($p = .43$) and between the 4 groups ($p = .11$), as well as in the mean increase or decrease in heart rate within each group ($p = .78$), and between the 4 groups ($p = .42$) from baseline to 60 minutes postadministration (Figures 2 and 3). None of the patients had tachycardia or bradycardia in the study.

A statistically significant increase in pupillary size (Figure 4) from baseline to 60 minutes postinstillation was seen in all of the 4 groups ($p < .05$). Among the 4 drugs, the mean pupillary size also increased significantly ($p < .05$). Groups A, B, and C all showed quick mydriasis from baseline to the 20th-minute mark then reached plateau thereafter. Group D had a slower onset of pupillodilation from baseline to 10 minutes, then showed a

steady increase up to the 30th-minute mark.

Table 2 shows a post hoc analysis using Tukey's honestly significant difference for all significant increases in pupil size observed. Among the five significant mean differences in pupillodilation across time, there was a significant difference in the rate of dilation with group B being faster than group D (mean difference 1.02 mm, 95% CI .61-1.4, $p < .05$). Groups A and B had the highest mean increase in pupil size across time, although much of the increase was observed within the first 20 minutes of administration, peaking at 10 minutes, and reaching plateau at 30 to 60 minutes.

DISCUSSION

A study involving 217 consecutive eyes in the same number of Chinese patients found that tropicamide 1% with phenylephrine 2.5% attained better preoperative mydriasis than tropicamide + phenylephrine 0.5% / 0.5%.

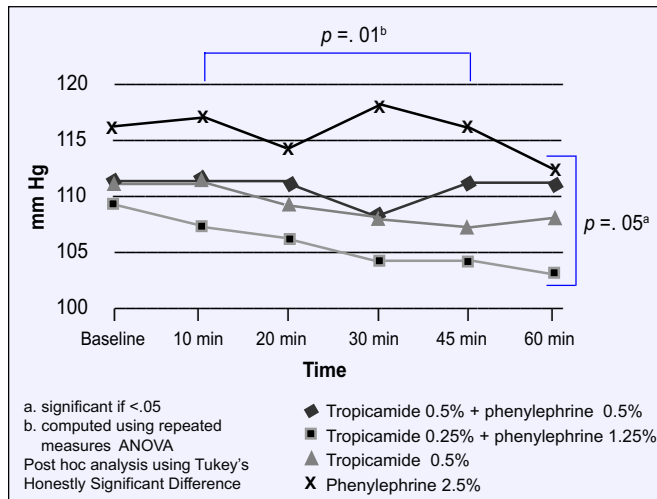


Figure 1. Mean systolic blood pressure across time.

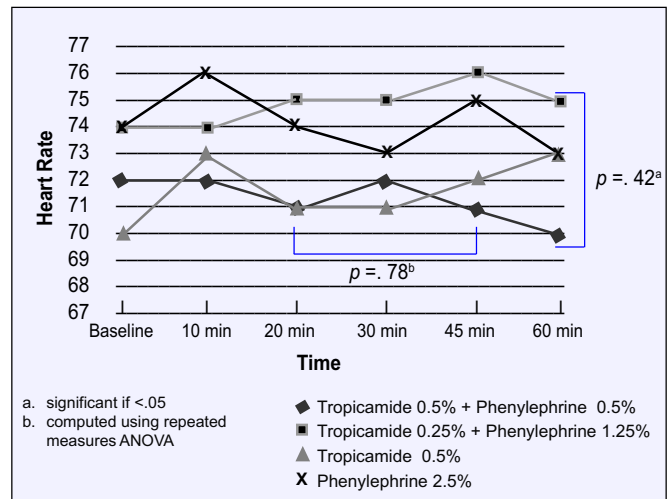


Figure 3. Mean cardiac rate across time.

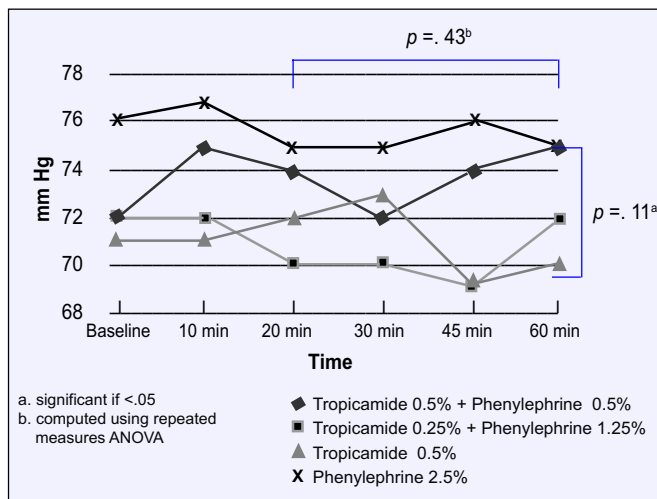


Figure 2. Mean diastolic blood pressure across time.

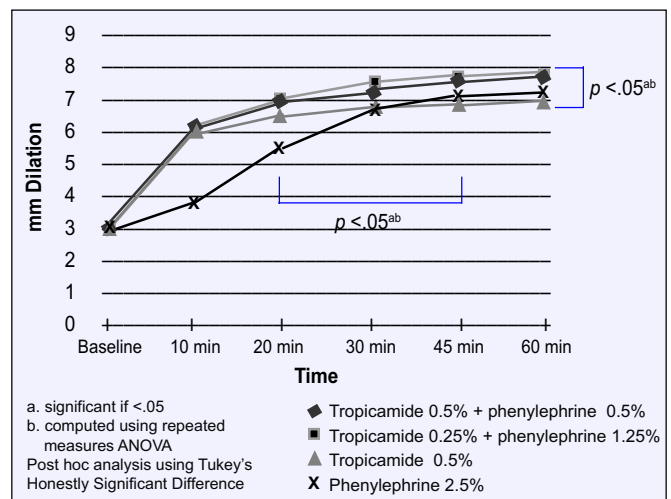


Figure 4. Mydriatic effect of the 4 drugs across time.

Both did not increase the blood pressure and heart rate. However, this study used only one eye per patient and a different concentration of tropicamide.⁸ A local study that compared phenylephrine 2.5% drops with and without the use of cotton pack also did not cause an increase in blood pressure and heart rate. This study involved the use of the same concentration of phenylephrine and was not compared with other mydriatic combinations.⁹

In our study, topical ophthalmic administration of the 4 drugs did not cause a significant increase in mean systolic or diastolic blood pressure and heart rate. One drop of 2.5% solution contains approximately 1.125 mg of phenylephrine. In the average adult, the lowest amount of phenylephrine to produce a pressor effect is 0.4 mg intravenously and 2 mg subcutaneously. The highest safe dosage is 1.5 mg intravenously and 300 mg subcutaneously.⁴ Assuming that the entire 1.125 mg is absorbed systemically, it may produce an increase in blood pressure. Although epithelial disruption following topical anesthesia may facilitate absorption of topical eye drops, the amount absorbed systemically depends on the dosage, application route, aqueous or viscous characteristics, dilution by lacrimation, and increased permeability of hyperemic conjunctival epithelium.¹⁰ While certain drugs are rapidly transported from the nasolacrimal system and absorbed into the vascular system, it is possible that a relatively small portion of commercially available phenylephrine is able to do so. This could be because the drug causes local vasoconstriction, there is diminished flow to an area with which it is in contact, or the patient complied well with instructions not to blink.

A drop in systolic blood pressure in all treatment groups was observed. It is possible that this may have occurred as a result of the calming effect of being instructed to sit still with the eyes closed.

Rapidity of dilatation saves time for both patient and physician. This study showed all 4 drug groups increased

pupillary size, but it was the tropicamide-phenylephrine 0.5%/0.5% and the self-prepared tropicamide 0.25%-phenylephrine 1.25% groups that produced rapid dilatation and did not have a significant effect on blood pressure. By eliminating the need for multiple instillation of two different drugs, the use of a single eye drop mydriatic combination is convenient in terms of time saved.

In conclusion, both tropicamide-phenylephrine 0.5%/0.5% and tropicamide-phenylephrine 0.25%/1.25% attained better dilation per unit time compared with phenylephrine 2.5% or tropicamide 0.5%. None of the medications caused an increase in the heart rate or blood pressure.

References

1. Van der Spek A, Hantler C. Phenylephrine eyedrops and anesthesia. *Anesthesiology* 1986; 64: 812-814.
2. Hardman JG, Goodman Gilman A, Limbird LE. *Goodman and Gilman's The Pharmacological Basis of Therapeutics*, 9th ed. New York: McGraw Hill, 1996; 1626-1628.
3. Apt L, Henrick A. Pupillary dilatation with single eyedrop mydriatic combinations. *Am J Ophthalmol* 1980; 89: 553-559.
4. Tang IH, Nishimoto J, Chang F. The effect of topical instillation of 2.5% phenylephrine and 1% tropicamide on the blood pressure of hypertensive patients. *Clinical Eye and Vision Care* 1997; 9: 227-231.
5. Fraunfelder FT, Scafidi A. Possible adverse effects from topical ocular 10% phenylephrine. *Am J Ophthalmol* 1978; 85: 447-453.
6. Kenawy NB, Jabir M. Phenylephrine 2.5% and 10% in phacoemulsification under topical anesthesia: is there an effect on systemic blood pressure? *Br J Ophthalmol* 2003; 87: 505-506.
7. Kumar V, Scheonwald RD, Chien DS, et al. Systemic absorption and cardiovascular effects of phenylephrine eyedrops. *Am J Ophthalmol* 1983; 99: 180-184.
8. Lam P, Poon B, Wu W, et al. Randomized clinical trial of the efficacy and safety of tropicamide and phenylephrine in preoperative mydriasis for phacoemulsification. *Clinical and Experimental Ophthalmology* 2003; 31: 52-56.
9. Fontanilla B, Aguilar R. Effect of 2.5% phenylephrine pack on blood pressure and pulse rate. *Philipp J Ophthalmol* 1999; 24: 81-85.
10. Brown M, Brown G, Spaeth G. Lack of side effects from topically administered 10% phenylephrine eyedrops: a controlled study. *Arch Ophthalmol* 1980; 98: 487-489.

Acknowledgment

The authors thank Dr. Joshua Marcos for his participation in this study.

ORIGINAL ARTICLE

Victor B. Lopez, MD
Maria Elizabeth T. Concepcion, MD

*Makati Medical Center
Makati City, Philippines*

Muller-muscle recession for mild to moderate upper-eyelid retraction

ABSTRACT

Objective

To describe a surgical procedure for the relief of mild to moderate upper-eyelid retraction secondary to Graves' ophthalmopathy using a graded, controlled recession of Muller muscle without recession of the levator aponeurosis.

Methods

Medical records of patients with mild to moderate upper-eyelid retraction secondary to Graves' ophthalmopathy who underwent Muller-muscle recession were reviewed. Five female patients 40 to 48 years of age were included. All were biochemically and clinically euthyroid for at least 6 months before the surgery. Patients had neither fibrosis nor exophthalmos. The outcome was evaluated 2 weeks after the operation by measuring the eyelid aperture and corneal light reflex to upper-lid-margin distance (MRD1) in the primary position. Patients were assessed to have upper-eyelid retraction when the MRD1 is > 4 . Corneal staining was assessed. Pre- and postoperative photographs were compared. The outcome was classified as good, acceptable, or unacceptable. The result was deemed stable if measurements remained unchanged during follow-up.

Results

Seven upper eyelids (of 5 patients) were corrected using Muller-muscle recession only. The procedure yielded good results in 2 cases of bilateral upper-eyelid retraction (MRD1 4.5 to 8 mm). For three patients who had unilateral upper-eyelid retraction (MRD1 4 to 8 mm), the results were good in 2 cases and acceptable in 1.

Conclusion

Muller-muscle recession is an effective means of relieving mild to moderate upper-eyelid retraction in patients with Graves' ophthalmopathy before fibrosis sets in.

Keywords: *Graves' ophthalmopathy, Graves' disease, lid retraction, Muller muscle, Exophthalmos*

Correspondence to
Victor B. Lopez, MD
Department of Ophthalmology
Carlos Sevilla Eye Center
Room 118, Makati Medical Center
2 Amorsolo Street
1229 Makati City, Philippines
Tel: +63-2-8929619
Fax: +63-2-8934367
E-mail: vblmd@pacific.net.ph

The authors have no proprietary or financial interest in any product used or cited in this study.

PHILIPP J OPHTHALMOL 2005; 30(1): 12-16

© PHILIPPINE ACADEMY OF OPHTHALMOLOGY

GRAVES' ophthalmopathy is believed to be a chronic autoimmune process with extrathyroidal manifestation. Orbital tissues are affected.^{1,2} Upper-eyelid retraction is a common finding in Graves' ophthalmopathy. It causes a startled or aggressive appearance, keratopathy, and ocular discomfort from globe exposure.³ Other symptoms are blurring of vision, orbital congestion, proptosis, and visual loss secondary to optic neuropathy.^{4,5} Graves' ophthalmopathy may also cause extraocular muscle dysfunction due to muscle fibrosis.⁶ In addition to its disfiguring and disabling effects, Graves' ophthalmopathy can also have negative influence on the patient's quality of life.⁷

Lid retraction may be caused by a number of factors namely overaction of the levator muscle, sympathetic overaction of the Muller muscle, contraction and degeneration of the levator muscle and aponeurosis, and adhesion between the levator and subcutaneous tissues. Thus, surgery for lid retraction is aimed at the levator complex and Muller muscles.⁸

Several lengthening procedures with variable rates of success have been proposed for upper-eyelid retraction in patients with Graves' ophthalmopathy.³ Recommended guidelines depend on the degree of lid retraction. Muller muscle surgery alone relieves 2 to 3 mm of lid retraction. Muller muscle and levator surgery relieves 4 to 6 mm of lid retraction. For greater lid retraction, spacers are considered. Once the lids are in appropriate position, further cosmetic procedures such as blepharoplasty, fat debulking or lateral tarsorrhaphy may be considered.⁹

Mild to moderate lid retraction may be corrected with a graded, controlled recession of the Muller muscle without recession of the levator aponeurosis. This is a relatively simple procedure that may be performed in the early phases of eyelid retraction (i.e., no exophthalmos and with minimal or no fibrosis). Because it is an outpatient procedure, it is convenient for both patient and physician. The ultimate goals are cosmetic rehabilitation and improvement of ocular discomfort and keratopathy. We present our experience with this technique.

METHODOLOGY

Medical records of patients with mild to moderate upper-eyelid retraction secondary to Graves' disease who underwent Muller-muscle recession alone between August 1993 and May 2004 were reviewed. Five females 40 to 48 years of age were included in the study. All had mild to moderate retraction within 12 months from onset. At the time of surgery, patients had been biochemically and clinically euthyroid for at least 6 months. Patients with other signs and symptoms of Graves' disease had been stable for at least 6 months before the eyelid surgery. Patients had no exophthalmos and no lid lag that signifies fibrosis. Lid lag is present when the upper lid fails to move

with the eye as the patient looks downward.

A complete eye examination that included measurement of the eyelid aperture and corneal light reflex to upper-eyelid-margin distance (MRD1) in the primary position of gaze was done.

In this study, MRD1 of >5 to 6 mm was classified as mild upper-eyelid retraction, >6 to 9 mm as moderate, and >9 mm as severe. Slit-lamp examination was performed to detect corneal staining. Patients had an endocrine clearance to ensure that the thyroid activity had been controlled for at least 6 months. All patients did not have exophthalmos based on the measurement using the Hertel exophthalmometer. Photographs of the eyes were taken before and after the eyelid-lengthening procedure.

All surgeries were performed by one surgeon (VBL). Two drops of proparacaine hydrochloride (Alcaine 0.5%, Alcon-Couvreur Puurs, Belgium) were administered on both eyes. The eyelids were cleaned and disinfected with povidone-iodine antiseptic. Sterile drapes were placed. The central upper-eyelid margin of the involved eye was infiltrated with 2% lidocaine with 1:100,000 epinephrine HCl (Hizon Laboratories, Manila, Philippines) (Figure 1a). An upper eyelid temporary suspension suture (Frost suture) was made using silk 4-0 (Figure 1b). The upper eyelid was inverted using a medium sized Desmarres retractor and the superior tarsal plate was identified (Figure 1c). The conjunctiva and the Muller muscle were ballooned with the anesthetic agent (Figure 1d). A conjunctival incision was performed and the Muller muscle was severed from its insertion in the superior tarsal plate (Figure 1e). The conjunctiva and the Muller muscle were dissected upward to the level of the superior fornix

Table 1. Assessment criteria for postoperative results.

Assessment	Criteria
Good	<ul style="list-style-type: none"> a. The upper 0.5 to 1.5 mm of the cornea in the 12 o'clock position is covered by the eyelid. b. The difference in the lid aperture between the left and right sides is < 1 mm. c. Patient is completely satisfied. d. Lid margin contour is smooth. e. Lid crease is within 7 to 10 mm from lid margin. f. The skin folds of the left and right lids are symmetrical.
Acceptable	<ul style="list-style-type: none"> a. The upper-eyelid margin is within 0.5 mm of the limbus, or covers no more than 2 mm of the cornea in the 12 o'clock position. b. The difference in the lid aperture between the left and right sides is less than 2 mm. c. The patient is satisfied and demands no further surgery. d-f. As in good result.
Unacceptable	One or more of the above criteria is/are not fulfilled.

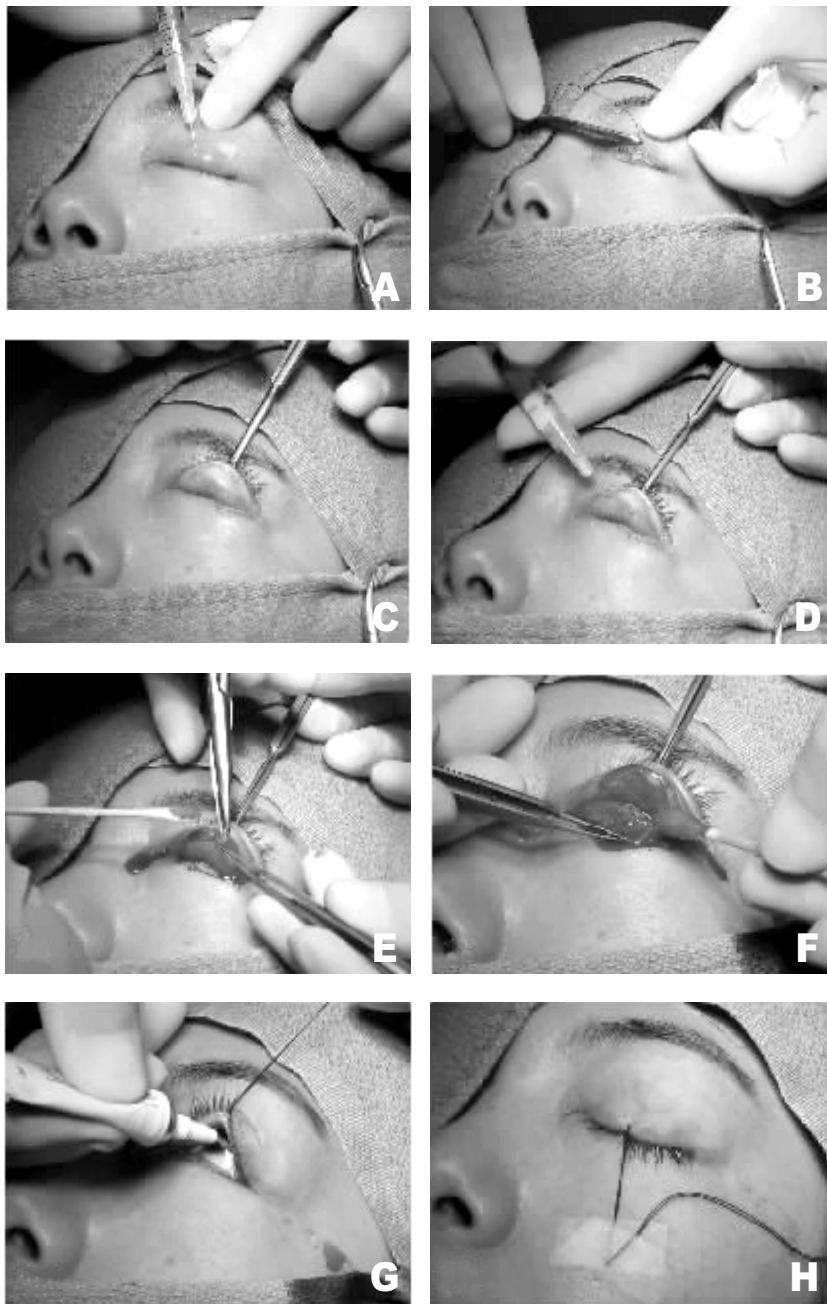


Figure 1. Muller-muscle recession: 2% lidocaine with 1:100,000 epinephrine HCl injected (A), Frost suture (B), upper eyelid inverted (C), conjunctiva and Muller muscle ballooned (D), conjunctival incision/Muller muscle severed (E), conjunctiva and Muller muscle dissected upward (F), eye closed and steroid-antibiotic ointment applied (G), Frost suture taped on the cheek and pressure dressing applied (H).

(Figure 1f). Phenylephrine 2.5% drops were instilled to cause retraction of the Muller muscle. The eye was closed and a steroid-antibiotic ointment was applied (Figure 1g). The Frost suture was taped on the cheek and pressure dressing was applied (Figure 1h). The dressing and the lid margin suture were removed one day after surgery. Tobramycin and dexamethasone (Tobradex, Alcon-Couvreur Puurs, Belgium) eyedrops were instilled for 7 to 10 days.

The outcome was evaluated by the senior surgeon 2 weeks after the

operation. The eyelid aperture and MRD1 in the primary position were measured, corneal staining was assessed, and pre- and postoperative photographs were compared. The outcome was classified as good, acceptable, or unacceptable (Table 1). Patients were reevaluated after 4 weeks and during subsequent follow-up to assess long-term results. The result was deemed stable if the measurements remained unchanged at follow-up.

RESULTS

Seven upper eyelids (of 5 consecutive patients) were corrected using Muller-muscle recession (Table 2). One patient had previous treatment (scleral graft) on the left upper lid. The indication for the lid surgery was primarily cosmetic rehabilitation in 3 patients. All patients were given artificial tears to relieve ocular discomfort prior to surgery.

Table 2 shows the pre- and postoperative MRD1. For patients with unilateral lid retraction, the MRD1 of the normal contralateral upper eyelid was used as the basis for correction of the affected upper lid to achieve symmetry. For those with bilateral lid retraction, the basis was normal MRD1 of 3 to 4 mm.

Muller recession achieved good results in two patients with bilateral upper-lid retraction (MRD1 of 4.5 to 8 mm). One of these patients underwent Muller recession of both lids in one setting. The other patient had unilateral lid retraction on initial visit and, only one lid was corrected. After a year, the other lid also had retraction and was corrected. Of these two patients, one underwent blepharoplasty of the right upper lid on follow-up. Neither patient had recurrence of lid retraction.

Three patients had unilateral upper-lid retraction (MRD1 of 4 to 8 mm). Surgical correction achieved good results in 2 cases (Figure 3 and 4). The second patient underwent blepharoplasty of the left lower lid on subsequent follow-up. The third patient had asymmetric lid contour and underwent release of lateral adhesion on the left eye a week after the Muller-muscle recession. No recurrence of lid retraction was seen on any patient on follow-up.

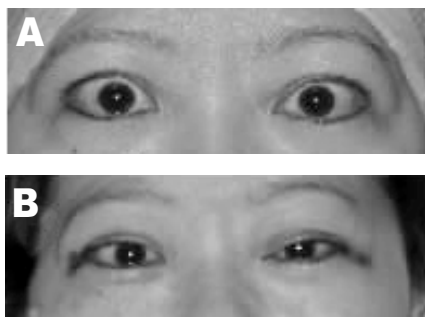

Figure 2. Patient with bilateral upper-lid retraction before (A) and after (B) correction. Good result. Good position, good contour. Left-right asymmetry less than 1 mm.

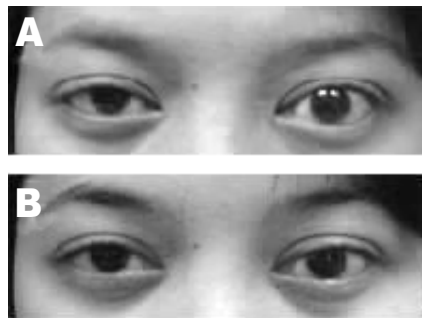

Figure 3. Patient with unilateral upper-lid retraction before (A) and after (B) correction. Good result. Good position, good contour. Left-right asymmetry less than 1 mm.

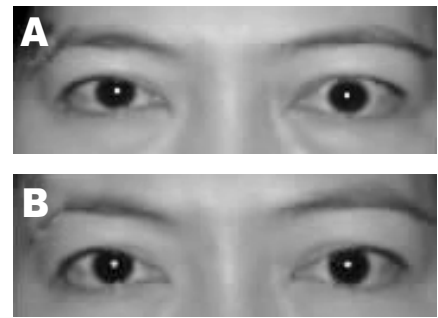


Figure 4. Patient with unilateral upper-lid retraction before (A) and after (B) correction. Good result. Good position, good contour. Left-right asymmetry less than 1 mm.

Table 2. Summary of the upper-eyelid retraction.

Patient	Age (Years)	Sex	Preop Right MRD	Postop Right MRD	Preop Left MRD	Postop Left MRD	Left-right Asymmetry	Procedure	Assessment of Outcome
Unilateral Muller Recession									
1	45	F	4 mm	4 mm	8 mm	4 mm	<1	Muller recession, left S/P Release of lateral adhesions, left	Acceptable
2	44	F	4 mm	4 mm	7 mm	3.5 mm	<1	Muller recession, left Blepharoplasty, lower lids	Good
3	40	F	4 mm	4 mm	7 mm	4 mm	<1	Muller recession, left	Good
Bilateral Muller Recession (in one setting)									
4	48	F	8 mm	4 mm	8 mm	4 mm	<1	Muller recession, right and left	Good
Bilateral Muller Recession (same person done within a year)									
5a	43	F	8 mm	4.5 mm	5 mm	5 mm	<1	Muller recession, right Blepharoplasty, right upper lid	Good
5b	43	F	4.5 mm	4.5 mm	8 mm	5 mm	<1	Muller recession, left	Good

DISCUSSION

Upper-eyelid retraction secondary to Graves' disease can trigger emotional and psychological problems in patients because of changes in physical appearance. Patients complain of cosmetic disfigurement and eye discomfort.¹⁰

Graves' ophthalmopathy has two stages: inflammatory (acute) and postinflammatory. The inflammatory stage usually lasts for three months to three years.^{7,11} Management at this stage includes temporary tarsorrhaphy or the use of lubricants or guanethidine to control the retraction. The inflammation must be stabilized for about six months before surgical correction of upper-lid retraction can be considered.^{12,13}

Upper lids can be lengthened by an anterior or a posterior approach. The type of surgery would depend on how the thyroid disease has affected the patient's eyes. Individuals may need one surgery or a combination of procedures. However, most of these procedures are done

when fibrosis and contracture of the lid retractor muscles have occurred. These lead to abnormal adhesion between the levator muscle and the surrounding fixed orbital tissues and to a widened palpebral fissure, which accentuates the proptosis.³ These procedures are considered cumbersome by some physicians because of the fibrosis encountered during dissection.

The patients involved in this series were all female, which may be because thyroid diseases affect more women than men.¹⁴

Patients underwent Muller-muscle recession under local anesthesia. They were awake, cooperative, and could be evaluated in an upright position during the procedure to ascertain the vertical eyelid position during and after surgery.

No fat debulking was done together with the Muller recession. No complication was encountered except for the occasional subcutaneous hematoma. During the follow-up period, all patients had almond-like contour of

the eyelids. No overcorrection was encountered that would have required reoperation. One patient needed a follow-up operation to release lateral adhesion due to reattachment. No recurrence of lid retraction or lid complication has been noted among the patients even after more than 10 years since surgery.

Our series demonstrated that Muller muscle recession alone is an effective means of relieving mild to moderate isolated upper-eyelid retraction in patients with Graves' ophthalmopathy and does not result in complications like exophthalmos. It can be performed by a general ophthalmologist on an outpatient basis. Surgical manipulation is minimal and just involves a transconjunctival incision, minimizing postoperative discomfort and any cutaneous scar. It is safe and recovery period is short. Most importantly, better outcome is achieved and the rate of recurrence of lid retraction is low.

References

1. Soares-Welch CV, Fatourehchi V, Bartley GB, et al. Optic neuropathy of Graves' disease: results of transantral orbital decompression and long-term follow-up in 215 patients. *Ophthalmology* 2003; 136: 433-441.
2. Wakelkamp IM, Tan H, Saeed P, et al. Orbital irradiation for Graves' ophthalmopathy, is it safe? A long term follow-up study. *Ophthalmology* 2004; 111: 1557-1562.
3. Mourits MP, Sasim IV. A single technique to correct various degrees of upper-lid retraction in patients with Grave's orbitopathy. *Br J Ophthalmol* 1999; 83: 81-84.
4. Ohtsuka K, Sato A, Kawaguchi S, et al. Effect of steroid pulse therapy with and without orbital radiotherapy on Graves' ophthalmopathy. *Ophthalmology* 2003; 35: 285-290.
5. Kalpadakis P, Rudolph G, Mueller A, Boergen KP. Muscle surgery in patients with Graves' disease using topical anesthesia. *Ophthalmology* 2004; 111: 1563-1568.
6. Kikkawa DO, Cruz RC, Christian WK, et al. Botulinum A toxin injection for restrictive myopathy of thyroid related orbitopathy: effects on intraocular pressure. *Ophthalmology* 2003; 135: 427-434.
7. Hosal B, Swanson J, Thompson CR, et al. Significance of serum antibodies reactive with flavoprotein subunit of succinate dehydrogenase in thyroid associated orbitopathy. *Br J Ophthalmol* 1998; 83: 605-608.
8. Khwarg SI, Lemke BN. Adjuvant lateral canthal advancement in the surgical management of exophthalmic eyelid retraction. *Ophthalmology* 1988; 117: 144-156.
9. Shah-Desai S. Management of eyelid retraction. *J Bombay Ophthal Assn* 2000; 10: 193-194.
10. Braverman LE. Thyroid gland disorders. In: Berkow R, Beers MH, Fletcher AJ, eds. *The Merck Manual of Medical Information*, home ed. New York: Merck & Co, Inc. 1997; chap 145.
11. Mercandetti M, Cohen AJ: Exophthalmos. *eMedicine Journal* 2001: <http://www.emedicine.com/oph/topic616.htm> (accessed March 18, 2004).
12. Harvey JT, Anderson RL. The aponeurotic approach to eyelid retraction. *Ophthalmology* 1981; 88: 513-524.
13. Lueder GI, Scott WE, Kutschke PJ, Keech RV. Long term results of adjustable suture surgery for strabismus secondary to thyroid ophthalmopathy. *Ophthalmology* 1992; 99: 993-997.
14. Gold JG, Sadeghi-Nejad A. Hyperthyroidism. *eMedicine Journal* 2002: <http://www.emedicine.com/ped/topic1099.htm> (accessed May 18, 2004).

ORIGINAL ARTICLE

Leandro Jose G. Domalanta, MD
Alex S. Sua, MD
Jocelyn L. Sy, MD

*University of Santo Tomas Hospital
Manila, Philippines*

Retinal toxicity of moxifloxacin injected intravitreally into rabbit eyes

A histological study

ABSTRACT

Objective

To investigate the retinal toxicity of different doses of moxifloxacin after intravitreal injection into rabbit eyes.

Methods

Eight male rabbits were divided into four groups; 2 rabbits each were injected intravitreally with moxifloxacin 48 μ g, 240 μ g, 480 μ g, and normal saline solution. Ocular toxicity was assessed at day 3 and day 7 by slit-lamp biomicroscopy, ophthalmoscopy, and histology.

Results

All eyes showed no abnormalities on histologic evaluation. No relevant complications were found during slit-lamp biomicroscopy and indirect ophthalmoscopy.

Conclusion

Intravitreal injection of 480 μ g or less of moxifloxacin did not produce retinal toxicity histologically in rabbit eyes.

Keywords: *Endophthalmitis, Retinal toxicity, Moxifloxacin, Intravitreal injection*

Correspondence to

Leandro Jose G. Domalanta, MD
Department of Ophthalmology
University of Santo Tomas Hospital
España Street, Sampaloc
1008 Manila, Philippines
Tel.: +63-2-7313001 ext. 2261
Email: jand018@yahoo.com

The authors have no proprietary or financial interest in any product used or cited in this study.

PHILIPP J OPHTHALMOL 2005; 30(1): 17-19

© PHILIPPINE ACADEMY OF OPHTHALMOLOGY

WITH MOST antibiotics, penetration into the vitreous cavity is poor when administered intravenously or orally.¹ Because of this, intravitreal injection is the preferred treatment for endophthalmitis. It improves outcome² because the antibiotic bypasses the blood-retinal barrier and rapidly achieves therapeutic drug levels. The ideal drug must not only show good activity against both gram-positive and gram-negative organisms but must also be tolerated by the ocular structures, particularly the retina.³ Intravitreal antibiotics can cause retinal toxicity and macular ischemia.^{4,5}

Moxifloxacin appears to exhibit efficacy against gram-

positive and gram-negative bacteria and is a promising agent for the treatment of endophthalmitis.⁶ This study determined the retinal toxicity of moxifloxacin.

METHODS

Eight adult male rabbits weighing 2.4 kg to 3 kg (mean 2.8 kg) were divided into 4 groups, each group injected intravitreally with moxifloxacin (Bayer AG, Levekusen, Germany) 48 μ g, 240 μ g, 480 μ g, and normal saline solution (NSS), respectively.

The animals were anesthetized with ketamine HCl at 10 mg/kg intramuscularly. A lid speculum was inserted.

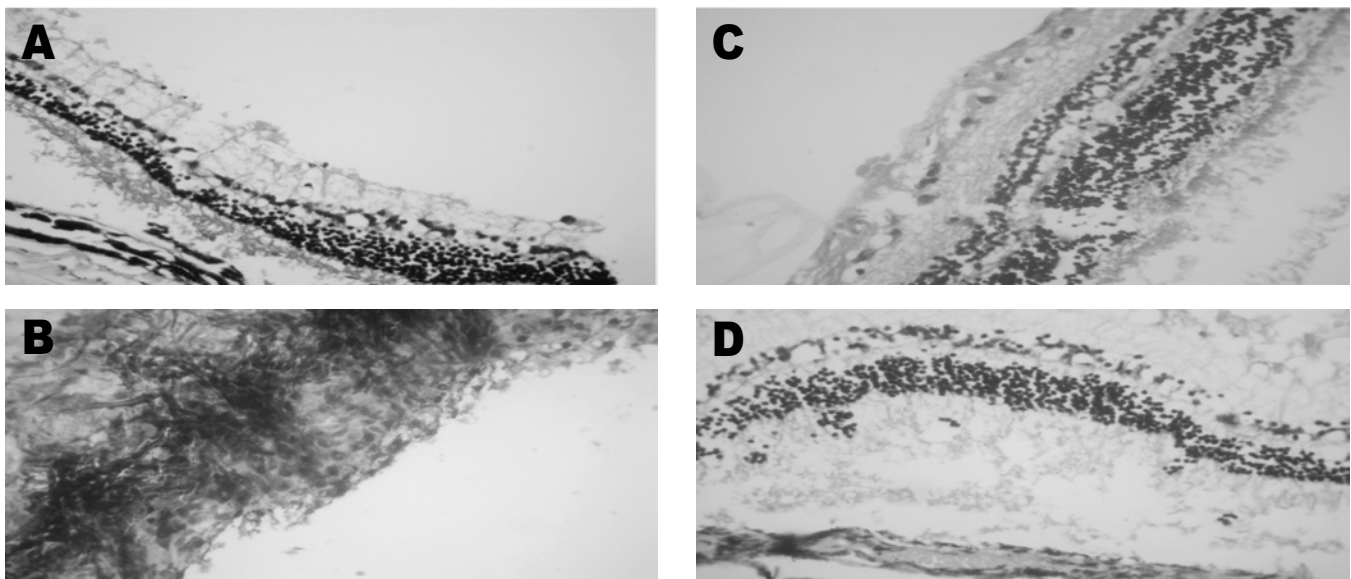


Figure 1. Histological section of the retina close to the optic nerve head on day 3 after intravitreal injection of NSS (A) and moxifloxacin 48 μ g (B), 240 μ g (C), 480 μ g (D). Photomicrographs demonstrate normal architecture with vacuoles in some retinal ganglion cells (400x).

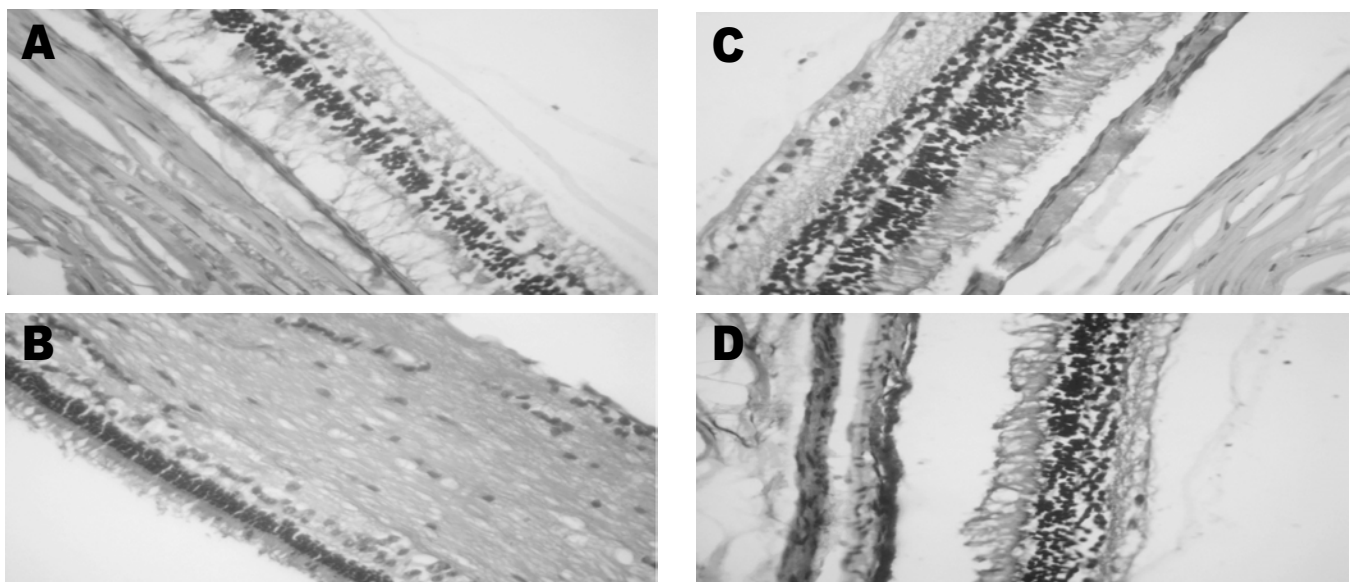


Figure 2. Histological section of the retina on day 7 after intravitreal injection of NSS (A) and moxifloxacin 48 μ g (B), 240 μ g (C), 480 μ g (D). Photomicrographs demonstrate normal architecture with vacuoles in some retinal ganglion cells (400x).

Povidone iodine solution was applied over the conjunctivae. Moxifloxacin was injected intravitreally into the right eye 2 mm from the limbus, close to the superior rectus muscle. Using a loupe 3x magnification, the injection was performed with tuberculin needle directed to the center of the vitreous cavity. 0.1 ml of aqueous humor was removed prior to the injection.

The eyes were evaluated by slit-lamp biomicroscopy before the injection and on the third and seventh day after. The pupils were dilated with topical tropicamide (Anten Pharmaceutical, Osaka, Japan) plus phenylephrine for fundus examination by indirect ophthalmoscopy. Three days after surgery, the right eye of one rabbit in each group was enucleated. The eyes of the remaining rabbits were enucleated at day 7. The enucleated eyes were fixed in 10% buffer formaldehyde and stored. Specimens from the peripheral retina, central retina, and optic nerve were obtained from each eye. The segments were embedded in paraffin and processed for light microscopy. Histologic preparations were stained with hematoxylineosin and toluidine blue.

The study complied with the guidelines of the Association for Research in Vision and Ophthalmology on the use of animals.

RESULTS

Slit-lamp biomicroscopy and ophthalmoscopy showed that all eyes were normal following intravitreal injection of moxifloxacin. Fundus examination did not show blood in the vitreous. No cataract nor retinal detachment was found. There were no abnormalities on gross and microscopic histopathology. All the eyeballs showed normal retinal architecture except for some empty vacuoles which were observed in both control and treated eyes (Figures 1 and 2).

DISCUSSION

Fourth-generation fluoroquinolones have been engineered to defy bacterial resistance. Earlier fluoroquinolones target the enzyme DNA gyrase (topoisomerase II) in gram-negative bacteria and topoisomerase IV in gram-positive bacteria. In contrast, fourth-generation quinolones block these enzymes simultaneously in both gram-positive and gram-negative bacteria. For resistance to occur, mutations would have to take place simultaneously at both sites. These drugs also combat bacterial efflux, a process by which the pathogens actively pump the drugs out of the cytoplasm.⁷

Side effects limit the systemic use of moxifloxacin and other quinolones.⁸ Previous studies have shown that moxifloxacin efficiently penetrates soft tissue^{9,10} and cerebrospinal fluid (CSF).¹¹ It also has an excellent penetration into the human aqueous humor, reaching

levels of $2.33 + 0.85 \mu\text{g/ml}$ 10 hours after a single oral 400-mg dose.¹² Tanahashi et al. suggested careful attention with higher doses of norfloxacin to be injected intravitreally.¹³ Ohkubo et al. observed retinal toxicity in higher doses of levofloxacin in rabbit retina.¹⁴

In our study moxifloxacin did not lead to funduscopy and histologic changes after intravitreal injection of 480 μg . This is way above the minimal inhibitory concentration (MIC) for most common microorganisms causing endophthalmitis such as staphylococcus, with MIC of 2.50 μg ¹⁵ and *Pseudomonas aeruginosa* with MIC of 8 μg .¹⁶

Moxifloxacin may be a potentially important drug in the treatment and prevention of clinical bacterial endophthalmitis. It has no evident retinal toxicity histologically in doses up to 480 μg . Future studies are needed to assess the intravitreal levels of moxifloxacin by high-performance liquid chromatography and to determine its elimination half life. An electroretinogram should be used to assess retinal function. Further studies in primates are required to confirm the efficacy and safety of this route of administration.

References

1. Barza M. Factors affecting the intraocular penetration of antibiotics. *Scand J Infect Dis* 1978;14: 151-159.
2. The Endophthalmitis Vitrectomy Study Group. The results of endophthalmitis vitrectomy study: a randomized trial of the immediate vitrectomy and of the intravenous antibiotics for treatment of postoperative bacterial endophthalmitis. *Arch Ophthalmol* 1995; 113: 1479-1496.
3. Peyaman GA, Herbst R. Bacterial Endophthalmitis. *Arch Ophthalmol* 1974; 91: 416-418.
4. Seawright AA, Bourke RD. Macula toxicity after intravitreal antibiotic. *Aust N Z J Ophthalmol* 1996; 24: 143-146.
5. Campochiaro PA, Conway BP. Aminoglycoside toxicity: a survey of retinal specialist—implications for ocular use. *Arch Ophthalmol* 1991; 109: 946-950.
6. Mather R, Kowalski RP, Withcher JP. Susceptibility test for bacterial endophthalmitis: *in vitro* study. *Am J Ophthalmol* 2002; 133: 163-165.
7. Mather R, Karenchak LM, Romanovski EG, et al. Fourth-generation fluoroquinolones: new weapons in the arsenal of ophthalmic antibiotics. *Am J Ophthalmol* 2002; 133:163-165
8. Ball P. Adverse reactions and interactions of fluoroquinolones. *Clin Invest Med* 1989; 12: 28-34.
9. Muller MH, Stass, M, Brunner JG, et al. Penetration of moxifloxacin into peripheral compartments in humans. *Antimicrob Agents Chemother* 1999; 43: 2345-2349.
10. Wise R, Andrews JM, Marshall G, Hartman G. Pharmacokinetics and inflammatory-fluid penetration of moxifloxacin following oral or intravenous administration. *Antimicrob Agents Chemoter* 1999; 43: 1508-1510.
11. Ostergaard C, Sorensen TK, Knudsen JD, Frimodt-Moller N. Evaluation of moxifloxacin, a new 8 methoxyquinolone, for treatment of meningitis caused by a penicillin-resistant pneumococcus in rabbits. *Antimicrob Agents Chemother* 1998; 42: 1706-1712.
12. Garcia-Saenz MC, Arias-Puente A, Fresnadillo-Martinez MJ, Carrasco-Font C. Human aqueous humor levels of oral ciprofloxacin, levofloxacin, and moxifloxacin. *J Cataract Refrac Surg* 2001; 27: 1969-1974.
13. Tanahashi T, Mochizuki K, Torisaki M, et al. Lens eye toxic effects of intravitreal injection of norfloxacin on the retina in pigmented rabbits. *Res* 1992; 9: 493-503.
14. Ohkubo S, Mochizuki K, Torisaki M, et al. Effects of intravitreal levofloxacin on the rabbit retina. *Nippon Ganka Gakkai Zasshi* 1996; 100: 592-598.
15. Han DP, Wisniewski SR, and Wilson LA. Spectrum and susceptibilities of microbiologic isolates in the endophthalmitis vitrectomy study. *Am J Ophthalmol* 1996; 122: 1-17.
16. Bayer product information.

Acknowledgment

The authors thank Drs. Jesus B. Eusebio Jr., Poderoso Casuela, Andrew Camara, and Ramon D. Boniol.

ORIGINAL ARTICLE

Jocelyn R. Elises, MD¹
Leo DP Cubillan, MD^{1,2}

¹ Department of Ophthalmology
and Visual Sciences
University of the Philippines-Philippine
General Hospital
Manila, Philippines

² Institute of Ophthalmology
University of the Philippines Manila
Manila, Philippines

Bonding strengths of 2-octyl cyanoacrylate, N-butyl-2-cyanoacrylate, and nylon 10-0

In experimental corneal perforations in porcine eyes

ABSTRACT

Objective

To determine the bonding strength of 2-Octyl cyanoacrylate (Dermabond) compared with N-Butyl-2-cyanoacrylate (Histoacryl) and nylon 10-0 (Alcon,) in sealing experimentally induced corneal perforations in cadaver porcine eyes.

Methods

This is a single-blind, randomized, physical experimental study involving 78 freshly enucleated porcine eyes in which perforations of 3.0 and 5.1 mm were made in the cornea and randomly sealed with either interrupted nylon 10-0 (n=13), Dermabond (n=13), or Histoacryl (n=13). Intraocular pressures were raised by injecting normal saline into the anterior chamber and postsealing leaking pressures were measured using a precalibrated manometer attached to the anterior chamber maintainer. Fisher's Exact Test was used to determine the difference in proportion of eyes that leaked, and Wilcoxon signed ranked test to compare the mean leaking pressures.

Results

In the 3.0 mm group, the proportion of eyes that leaked in Dermabond (2/13, 15.4%) and Histoacryl (1/13, 7.7%) were comparable ($p = 1.00$). Proportion of leak in nylon 10-0 (13/13, 100%) was significantly higher ($p < 0.001$). Mean leaking pressures of Dermabond (79.5 mm Hg) and Histoacryl (88.0 mm Hg) were higher compared with that of nylon 10-0 (61.44 mm Hg) ($p < 0.05$). In the 5.1 mm group, proportion of eyes that leaked in Dermabond (4/13, 30.8%) and Histoacryl (2/13, 15.4%) were comparable ($p = 0.65$). Proportion of leak in nylon 10-0 (13/13, 100%) was significantly higher ($p < 0.001$). Mean leaking pressures of Dermabond (92.75 mm Hg) and Histoacryl (86.5 mm Hg) were higher than that of nylon 10-0 (59.08 mm Hg) ($p = 0.07$ and $p = 0.10$).

Conclusion

The bonding strengths of Dermabond and Histoacryl are comparable and greater than that of nylon 10-0. Both are effective for 3.0 mm and 5.1 mm corneal perforations.

Keywords: Corneal perforations, 2-Octyl cyanoacrylate, N-butyl-2-cyanoacrylate

Correspondence to
Jocelyn R. Elises, MD
Department of Ophthalmology and Visual Sciences
University of the Philippines-Philippine General Hospital
Taft Avenue, Ermita
1000 Manila, Philippines
Tel. +63-2-3022486 to 90
E-mail: j_elises@yahoo.com

The authors have no proprietary or financial interest in any product used or cited in this study.

LACERATIONS and perforations of the cornea are considered ophthalmic emergencies. Trauma is the leading cause of partial- and full-thickness corneal lacerations. Conditions such as microbial keratitis, keratoconjunctivitis sicca, neurotrophic or exposure keratopathy, and corneal ectasias may lead to corneal perforations. Disastrous sequelae of corneal lacerations and perforations include corneal scarring, infection, synechiae formation, cataract, glaucoma, and blindness. Prompt and effective treatment of these lacerations and perforations lessens the risk of these complications. Treatment options for corneal lacerations and perforations include suturing, corneal patch grafting, penetrating keratoplasty, keratoprosthesis, and closure with tissue adhesives.¹

In corneal lacerations, particularly in perforations, the maintenance of a watertight anterior chamber with no synechiae is important. Perforations are sealed with agents that appose wound edges and keep them watertight. The method mostly used to seal such perforations is suturing.²

The use of sutures in sealing corneal perforations is, however, not without complications. In sealing corneal lacerations, suturing has been known to cause significant astigmatic error as well as cheesewiring, inflammation, loosening, neovascularization, necrosis, and infection. When such complications arise, the patient will have to undergo suture removal, which in children and uncooperative adults is difficult to do.²

Sutureless procedures using glues are advantageous because these techniques immediately restore the integrity of the globe and decrease the risk of complications. Biologic glues include fibrin tissue adhesive or fibrin glue (Beriplast P, Aventis) while N-Butyl-2-cyanoacrylate (Histoacryl, Braun) is the more commonly used chemical glue for corneal surgery (off-label use).

Fibrin glue and N-butyl-2-cyanoacrylate as tissue adhesives for corneal perforations have been found effective in closing corneal perforations up to 3 mm, although fibrin glue takes a longer time for adhesive plug formation than N-butyl-2-cyanoacrylate.³ Commercially produced fibrin tissue adhesive from pooled blood is biodegradable, but because of fear of viral contamination with hepatitis B, hepatitis C, or the human immunodeficiency virus, it is not approved by the United States Food and Drug Administration (FDA).⁴

Cyanoacrylate adhesives were first described in 1949. Cyanoacrylate forms a strong bond once it polymerizes. Polymerization of the adhesive occurs when water or any basic substance gets in contact with it, producing an exothermic reaction. Over the years, several cyanoacrylate monomers have been developed as tissue adhesives. However, their clinical use has been limited because of their physical properties.

Butyl cyanoacrylate derivatives are commercially available tissue adhesives not yet approved by the FDA for clinical use. Cyanoacrylate tissue adhesives have many favorable properties—including strong bonding, short polymerization time, and relatively low cost—that some ophthalmologists use it for ocular surgery. Unfortunately, some cyanoacrylate derivatives can cause histotoxic effects because they degrade into formaldehyde and cyanoacetate. The degree of acute inflammation is inversely proportional to the length of the monomer chain. Among the longer-chain derivatives is 2-Octyl cyanoacrylate, a combination of monomers and plasticizers that forms a strong flexible bond. It has a three-dimensional breaking strength four times that of N-butyl-2-cyanoacrylate. 2-Octyl cyanoacrylate shows lower toxicity than N-butyl-2-cyanoacrylate because of decreased by-product formation of formaldehyde.^{5, 6, 7}

In 2001, the FDA approved the use of 2-Octyl cyanoacrylate in sealing small skin incisions and lacerations. It naturally sloughs off the skin in 5 to 10 days. It is also 99-percent effective in protecting against *Staphylococcus epidermidis*, *Escherichia coli*, *Staphylococcus aureus*, *Pseudomonas aeruginosa* and *Enterococcus faecium*, acting as a microbial barrier. After the wound has been cleaned, the edges are apposed and 2-Octyl cyanoacrylate is applied in layers (minimum of 3) with a light brushing stroke. It forms a strong, flexible bond in just 45 to 60 seconds and reaches full strength in approximately 2 minutes and 30 seconds. The incision site need not be kept dry.⁸

Successful treatment of a corneal perforation with 2-Octyl cyanoacrylate has been reported by Taravella et al. After application of the glue, the anterior chamber deepened and the visual acuity improved. The glue remained intact for 6 weeks and eventually fell off.⁹ Since 2-Octyl cyanoacrylate forms a waterproof dressing, it may even be used on frequently wet surfaces like the cornea.

To understand the sealing properties of cyanoacrylate adhesive, we compared the bonding strengths of corneal perforations sealed with 2-Octyl cyanoacrylate (Dermabond, Johnson & Johnson, New Brunswick, NJ, USA), N-Butyl-2-Cyanoacrylate (Histoacryl, B. Braun, Melsungen, Germany), a commonly used adhesive, and Nylon 10-0 (Alcon, Fort Worth, TX, USA), the gold standard, by determining the leaking pressures as measured by a manometer attached to the anterior-chamber maintainer of the eye.

METHODOLOGY

This is a single blind, completely randomized physical experimental animal study. The sample size per treatment group of 13 eyes was computed using a power of 95%, confidence interval of 5%, standard deviation of 6, and a maximum tolerable level of 7 mm Hg.

Seventy-eight freshly enucleated porcine eyes with average corneal diameter of 14.5 mm and baseline Schiøtz intraocular pressure of 17.3 mm Hg were randomly assigned to the 3.0 mm (n=39) and the 5.1 mm perforation groups (n=39). All perforations were made perpendicular to the corneal surface with a fresh 3.0 mm or 5.1 mm metal keratome at the central portion of the cornea.

Thirteen corneal perforations in each group were sealed either with nylon 10-0 sutures, Dermabond, or Histoacryl by random allocation. In the sutured corneas, the 3.0 mm perforations were sealed with 1 suture while the 5.1 mm perforations were sealed with 2 sutures. In those sealed with Dermabond, the wound edges were dried and the tissue adhesive was applied thinly 3 times using the applicator tip with a brushing motion parallel to the corneal perforation. In those sealed using Histoacryl, the wound edges were dried and a drop of tissue adhesive was applied and spread across the perforation. In both Dermabond and Histoacryl groups, the eye was irrigated with normal saline solution after application of the tissue adhesive for polymerization to occur.

An anterior chamber maintainer was inserted through a 1 mm stab incision. Intraocular pressure was raised by injecting normal saline through the anterior-chamber maintainer immediately after suturing and 3 minutes after polymerization of both Dermabond and Histoacryl. A manometer, precalibrated up to 100 mm Hg, was attached to the end of the anterior-chamber maintainer to determine the intraocular pressure. The post-sealing intraocular leaking pressures were recorded with the reader blinded as to the treatment groups. Wound leak was determined using Seidel's test. No leak was recorded if the Seidel's test was negative when the intraocular pressure was raised to 100 mm Hg, the highest reading in the precalibrated manometer used.

The proportion of eyes that leaked and the mean leaking pressures were computed. Fisher's Exact Test (Stata Corporation, College Station, TX, USA) was used to determine the difference in the proportion of eyes that leaked between the treatment groups. Wilcoxon signed ranked test was used to compare the mean leaking pressures of eyes that leaked between the treatment groups.

RESULTS

Included were 78 porcine eyes, distributed equally into 3 mm and 5.1 mm perforation groups. Each perforation group was divided into three types of sealing methods: 2-Octyl cyanoacrylate, N-butyl-2-cyanoacrylate, and nylon 10-0; total of 13 samples each.

In the 3 mm corneal perforation group, only 2 (15.4%) of the 13 eyes sealed with 2-Octyl cyanoacrylate leaked (Table 1). Mean leaking pressure was 79.5 mm Hg. Only 1 (7.7%) of the 13 eyes sealed with N-butyl-2-cyanoacrylate leaked. Leaking pressure was 88.0 mm Hg. All of the 13 eyes sutured with nylon 10-0 leaked. Mean leaking pressure was 61.44 mm Hg. The proportions of eyes that leaked in both the 2-Octyl cyanoacrylate and the N-butyl-2-cyanoacrylate groups were comparable ($p = 1.00$). The proportion of eyes that leaked in the nylon group, however, was significantly higher ($p < 0.001$) than the other 2 groups. The mean leaking pressure of 2-Octyl cyanoacrylate was higher compared with that of the nylon 10-0 group ($p = 0.16$). Similarly, the leaking pressure of the N-butyl-2-cyanoacrylate group was higher than the nylon 10-0 group ($p = 0.32$).

In the 5.1 mm corneal perforation group, 4 (30.8%) of the 13 eyes sealed with Dermabond leaked (Table 1). Mean leaking pressure was 92.75 mm Hg. In the Histoacryl group, 2 (15.4%) of the 13 eyes leaked. Mean leaking pressure was 86.5 mm Hg. All of the 13 eyes sutured with nylon 10-0 leaked. Mean leaking pressure was 59.08 mm Hg. The proportions of eyes that leaked in both the Dermabond and Histoacryl groups were comparable ($p = 0.65$). The proportion of eyes that leaked in the nylon 10-0 group, however, was significantly higher ($p < 0.001$) compared with both the Dermabond and Histoacryl groups. The mean leaking pressure of Dermabond was higher compared with the nylon 10-0 group ($p = 0.07$). Similarly, the mean leaking pressure of the Histoacryl group was higher compared with the nylon 10-0 group ($p = 0.10$).

DISCUSSION

Bonding strength is the ability of the tissue edges to remain apposed and maintain a watertight anterior chamber in corneal perforations. In this study, bonding strength was determined by measuring the leaking pressures of sealed experimental perforations. Bonding strengths of nylon 10-0, Dermabond, and Histoacryl were determined and compared.

Results showed that in the 3.0 mm perforation group, the mean leaking pressure of Dermabond was lower than

Table 1. Eyes that leaked and mean leaking pressure in the 3 mm and 5.1 mm perforation groups.

Treatment Type	N	Number of Eyes that Leaked (Percent)		Mean Leaking Pressure (mm Hg)	
		3 mm	5.1 mm	3 mm	5.1 mm
2-Octyl cyanoacrylate (Dermabond)	13	2 (15.4)	4 (30.8)	79.50 ± 2.12	92.75 ± 7.41
N-butyl-2-cyanoacrylate (Histoacryl)	13	1 (7.7)	2 (15.4)	88	86.50 ± 7.78
Nylon 10-0 (Alcon)	13	13 (100)	13 (100)	61.54 ± 3.97	59.08 ± 4.29

that of Histoacryl but higher than that of nylon 10-0. In the 5.1 mm perforation group, however, the mean leaking pressure of Dermabond was higher compared with those of Histoacryl and nylon 10-0. The differences in mean leaking pressures, however, were not statistically significant. The results of this study do not support the findings by Quinn in 1997 that compared sutures and 2-Octyl cyanoacrylate in sealing skin lacerations. Quinn reported that N-butyl-2-cyanoacrylate formed a strong bond that was brittle and prone to fracture when used on long lacerations. 2-Octyl cyanoacrylate has a longer-chain formulated cyanoacrylate containing monomer and plasticizers. This produces a stronger, flexible, 3-dimensional bond more suited for longer lacerations. The study concluded that 2-Octyl cyanoacrylate is more effective than N-butyl-2-cyanoacrylate for longer skin lacerations.⁵ Our study showed that both have comparable bonding strengths and are effective in sealing 3 mm and 5.1 mm corneal perforations.

The proportion of leak among porcine eyes sealed with Dermabond is significantly lower compared to that of eyes sealed with nylon 10-0. The proportion of leak among porcine eyes sealed with Dermabond is comparable to that of Histoacryl. This difference is not statistically significant.

In this study, the bonding strengths (in terms of leaking pressure) of corneal perforations sealed with 2-Octyl cyanoacrylate and N-butyl-2-cyanoacrylate are comparable and greater than that of nylon 10-0. These two tissue adhesives are both effective in sealing 3.0 mm and 5.1 mm corneal perforations.

References

1. Miki D, Dastgheib K, Kim T, et al. A photopolymerized sealant for corneal lacerations. *Cornea* 2002; 21: 393-399.
2. Santos M, Flores J. Wound strength of experimental corneal perforations sealed with fibrin glue in cadaver porcine eyes. *Philipp J Ophthalmol* 2002; 27: 59-63.
3. Sharma A, Kaur R, Kumar S, et al. Fibrin glue versus n-butyl-2-cyanoacrylate in corneal perforations. *Ophthalmology* 2003; 110: 291-298.
4. Siedentop K, Park J, Sanchez B. An autologous fibrin tissue adhesive with greater bonding power. *Arch Otolaryngol Head Neck Surg* 1995; 121:769-772.
5. Quinn J, Wells G, Sutcliffe T, et al. A randomized trial comparing octylcyanoacrylate tissue adhesive and sutures in the management of lacerations. *JAMA* 1997; 227: 1527-1530.
6. Macsai M. The management of corneal trauma: advances in the past twenty-five years. *Cornea* 2000; 19: 617-624.
7. Gosain AK, Lyon, VB. The current status of tissue glues: part II for adhesion of soft tissues. *Plast and Reconstr Surg* 2002; 110: 1581-1584.
8. Johnson & Johnson, Dermabond Topical Skin Adhesive. <http://www.dermabond.com.htm> (accessed July 30, 2003).
9. Taravella MJ, Chang CD. 2-Octyl cyanoacrylate medical adhesive in treatment of a corneal perforation. *Cornea* 2001; 20: 220-221.

Acknowledgment

The authors thank Drs. Amor Y. De la Cruz and Sheila Marie Lavina for their invaluable support.

ORIGINAL ARTICLE

Rey Matanguihan, MD
James Co Shu Ming, MD
Processo Surrell, MD

*East Avenue Medical Center
Quezon City, Philippines*

Axial-length computation using corneal dimensions and A-scan biometry

A comparison

ABSTRACT

Objective

To compare the axial length derived from a formula incorporating corneal dimensions with the results obtained by A-scan biometry.

Methods

This is a nonrandomized comparative study of patients from the outpatient department of a tertiary-care academic medical institution who were screened for cataract surgery. Corneal diameter and slope were measured with a Vernier no. 6 caliper and axial length determined using Ophthasonic A-Scan III machine. Computed axial lengths were arrived at using a formula incorporating corneal diameter and slope. The mean difference of measured and computed axial lengths were statistically analyzed using paired *t* test and general linear model tests.

Results

A total of 105 eyes (96 patients) were included in the study. The mean difference between computed and measured axial lengths was not statistically significant ($p = 0.64$ for computed axial length < 22.00 mm, $p = 0.11$ for computed axial length of 22.00 to 22.99, $p = 0.81$ for computed axial length of 23.00 to 23.99, and $p = 0.03$ for computed axial length ≥ 24.00 mm).

Conclusion

Axial length measured with an A-scan can be reliably approximated by using Surrell's formula based on corneal length measurements.

Correspondence to
Rey T. Matanguihan, MD
East Avenue Medical Center
East Avenue, Diliman
1104 Quezon City, Philippines
Tel. +63-2-9288550
E-mail: reymatt@yahoo.com

Keywords: Axial length, Corneal diameter, Corneal slope, Biometry

The authors have no proprietary or financial interest in any product used or cited in this study.

PHILIPP J OPHTHALMOL 2005; 30(1): 24-27

© PHILIPPINE ACADEMY OF OPHTHALMOLOGY

THE INTRODUCTION of new technologies such as ultrasound and the keratometer has made it possible to measure the axial length and corneal curvature for estimating intraocular-lens (IOL) power. Subsequent large-scale population studies have led to the development of linear regression formulas, the most popular of which is the SRK II formula named after its authors Sanders, Retzlaff, and Kraff.

These new technologies are hardly available in many areas in the Philippines. For instance, most of the 700 or so cataract surgeries performed in outreach surgical missions by the Department of Ophthalmology of the East Avenue Medical Center were done without the use of automated biometry machines. Many of these surgeries used IOLs within 20 to 22 D. La Nauze showed in a study of 346 Vietnamese adults that the mean IOL power for emmetropia was 20.72 D for males and 21.94 D for females.¹ About 95% of their study population were within 5.5 D of these mean results. No similar study on Filipinos has been published.

The need for a system of determining a suitable IOL without relying on biometry machines was addressed by Processo Surrell in a 2002 pilot study where he used a formula for computing IOL power based on measurements of the corneal diameter and height.² He based his computations on two assumptions: the eyeball is composed of two unequal spheres (corneal and sclera) fused at the limbus; the sclera covers 300 degrees while the cornea covers the rest. He then devised a formula for axial-length computation based on a system of triangles and principles of the Pythagorean system as follows:

$$AXL = \sqrt{C^2 - \left[\frac{D}{2}\right]^2} + \sqrt{D^2 - \left[\frac{D}{2}\right]^2} + D$$

where AXL = axial length
 C = corneal height/slope
 D = corneal diameter (Figure 1).

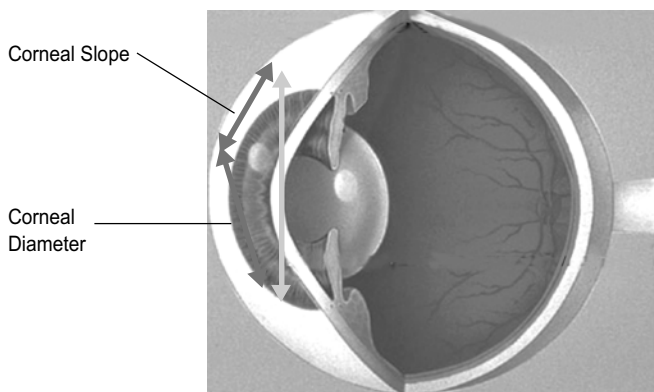


Figure 1. Corneal diameter and slope in relation to the eyeball.

In a study of 30 eyes, Surrell found no significant statistical difference between biometry readings and the axial length, keratometry, and IOL power derived from this formula.

Determination of axial length is an important step in IOL estimation. As early as 1992, Olsen had already noted in a study of 584 IOL implantations that as much as 54% of the error was attributed to axial-length discrepancies.³ Since then, few studies have explored the relationship of the cornea and axial length. Touzeau compared biometric parameters measured with Orbscan with the subjective spherical equivalent of 190 eyes of 95 patients.⁴ Corneal biometric parameters did not correlate with refractive error but a strong correlation between corneal radius and axial length was seen. Yebra-Pimentel found a direct relationship between the axial-length-to-corneal-radius (AL/CR) ratio and the refractive error in hyperopes, emmetropes and low myopias.⁵

This study compared computed axial length using Surrell's formula with readings retrieved from automated biometry measurements using the A-scan. We hypothesized that the results of the two methods would be the same and may then be used in subsequent studies of IOL determination using clinical measurements.

METHODOLOGY

This is a comparative, nonrandomized study of patients from the outpatient department of a tertiary-care academic medical institution who were screened for cataract surgery from April 1, 2004 to September 1, 2004. Patients with a history of eye trauma and ocular surgery and those previously diagnosed with gross abnormalities of size and shape of the cornea and sclera were excluded. Main outcome measures were corneal diameter, corneal slope, and axial length.

The corneal diameter and slope were measured at the outpatient department. The patients were made to lie supine on a flat bed. Topical anesthesia was administered and a lid retractor placed. The horizontal and vertical corneal diameters were measured (Figure 2) using the anterior edge of the gray transition zone between the clear cornea and limbus as landmarks at the 3 and 9 o'clock and 6 and 12 o'clock positions under a microscope with a plastic Vernier caliper (Hangzhou Jinnan Tools and Measure Co. Ltd., China). The caliper is accurate up to 0.05 millimeter.

The corneal slope is the distance measured from the center of the cornea to the landmarks of the gray transition zone at the 3, 6, 9, and 12 o'clock positions (Figure 3). Corneal measurements were done 3 times by a single examiner and results were encoded in MS Excel (Microsoft Corporation, Redmond, Washington, USA). The axial lengths were computed using Surrell's formula for each

of the 4 meridians and the average axial length was labeled as the "Computed AXL." Corresponding axial-length values were measured three consecutive times by another masked observer using Ophthasonic A-Scan III machine (Teknar Ophthasonic A-scan III, Teknar, St. Louis, MO, USA) and the values were recorded as "Measured AXL." All data were recorded up to one-hundredth of a millimeter.

The precision of computed axial length was defined as standard deviation of the difference between computed and measured axial-length values. Student *t* test compared the average of the "Computed AXL" values versus the average "Measured AXL" at $p < 0.05$ for statistical significance, using SPSS 10.0 for Windows (SPSS Inc., Chicago, IL, USA).

RESULTS

A total of 105 eyes (96 patients; 47 males, 49 females; ages 20 to 78) were included in the study. Computed axial lengths ranged from 21.10 to 24.41 mm, with a mean of $22.94 \text{ mm} \pm 0.65 \text{ mm}$ (Table 1). Measured axial lengths ranged from 20.81 to 26.43 mm, with a mean of $23.06 \text{ mm} \pm 0.99 \text{ mm}$. Figure 4 shows a plot of the computed axial lengths with the corresponding measured axial length in ascending order.

The mean difference between measured and computed axial was $+0.12 \text{ mm} \pm 0.66 \text{ mm}$ (range of -1.62 to $+2.08 \text{ mm}$). Figure 5 shows a scatter graph plotting the difference between measured and computed axial length values. A positive or negative value means that the computed axial length was either overestimated or underestimated compared with the corresponding A-scan measurement.

The difference between computed and measured axial lengths for the whole study population was not statistically significant ($p = 0.08$, 95% CI). Neither was the difference statistically significant for axial lengths less than 22.00 mm ($p = 0.64$), 22.00 to 22.99 mm ($p = 0.11$), 23.00 to 23.99 mm ($p = 0.81$). However, the difference was significant for axial length of 24.00 mm or greater ($p = 0.03$) (Table 1).

Table 1. Mean computed and measured AXL.

Computed AXL	N	Computed AXL	Measured AXL	Paired <i>t</i> test
All	105	23.05 ± 0.99	22.93 ± 0.64	$p = 0.08$
< 22.00 mm	8	21.67 ± 0.28	21.74 ± 0.59	$p = 0.64$
22.00 to 22.99 mm	52	22.65 ± 0.29	22.78 ± 0.71	$p = 0.11$
23.00 to 23.99 mm	38	23.37 ± 0.27	23.34 ± 0.81	$p = 0.81$
> 24.00 mm	7	24.22 ± 0.17	24.97 ± 0.82	$p = 0.03$

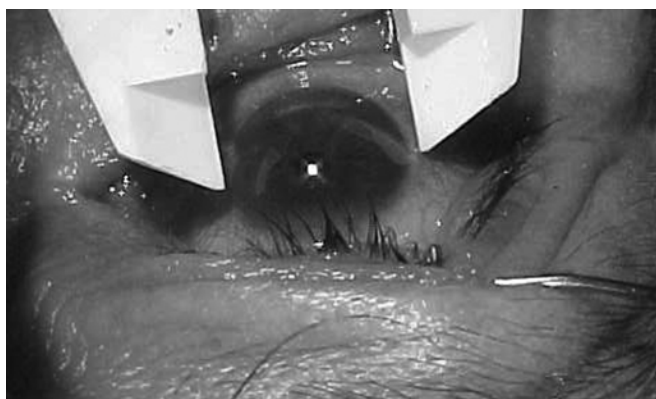


Figure 2. Measurement of corneal diameter.

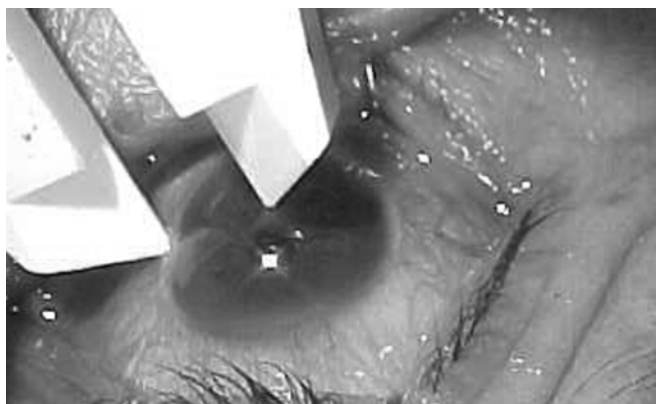


Figure 3. Measurement of corneal slope.

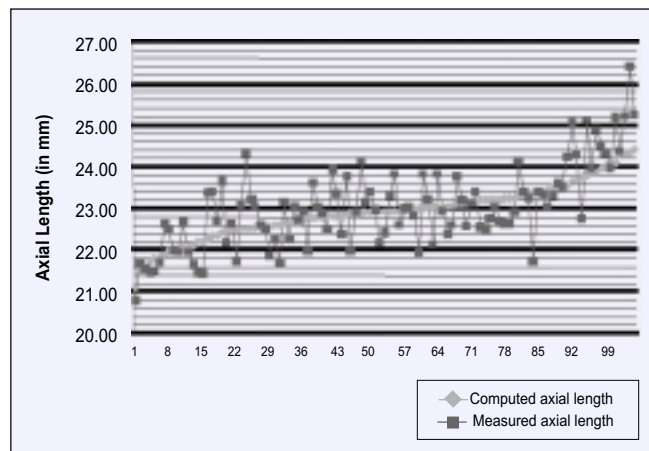


Figure 4. Computed axial length versus measured axial length.

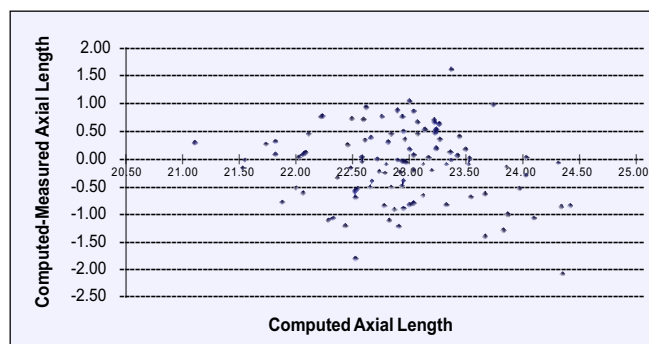


Figure 5. Difference between computed and measured axial length.

DISCUSSION

The results indicate that the axial length obtained from measurements of the corneal diameter and slope approximates that obtained by A-scan biometry. The results are important in relation to the determination of IOL power. When applying the SRK II formula to compute for the difference in IOL power using the mean computed and measured axial lengths for the whole subject population, the 0.12 mm difference translates to a 0.30 diopter IOL discrepancy. The diopter IOL discrepancy was 0.175 (from mean difference of 0.07 mm) in the group with computed axial length of < 22.00 mm, 0.325 (from mean difference of 0.14 mm) in the group with computed axial length of 22.00 to 22.99 mm, 0.075 (from mean difference of 0.03 mm) in the group with computed axial length of 23.00 to 23.99 mm, and 1.875 (from mean difference of 0.75 mm) in eyes with computed axial length of 24.00 mm and greater.

Although the methodology is simple, interobserver variability may exist and alter the computed axial length due to differences in identifying corneal/limbal landmarks, the positioning of the caliper, and reading the measurements on the scale. Surell's formula assumes that the cornea and the globe are two unequal perfect spheres. In reality, imperfections in the actual shape of the eyeball

become sources of error when calculating for the axial length this way. This is obviated with direct ultrasound measurements in the A-scan method.

In summary, this study showed that axial-length computation using the Surell formula can reliably approximate the actual axial length measured by A-scan and, in cases where an ultrasound machine is not available, may be used to determine the correct IOL power for patients about to undergo cataract surgery.

References

1. La Nauze J, Kim Thanh T, et al. Intraocular-lens-power prediction in a Vietnamese population: a study to establish a limited set of intraocular-lens powers that could be used in a Vietnamese population. *Ophthalmic Epidemiology* 1999; 6:147-158.
2. Surrrell P, Co Shu Ming J, Del Mundo J. Formulas based on geometric properties of the eye in intraocular-lens-power calculation. Philippine Academy of Ophthalmology. <http://www.pao.org.ph/main.php?fid=annual/abs2002bt7>.
3. Olsen T. Sources of error in intraocular-lens-power calculation. *J Cataract Refract Surg* 1992; 18: 125-129.
4. Touzeau O, Allouch C, Borderie V, et al. Correltion entre la refraction et la biometrie oculaire. *J Fr Ophthalmol* 2003; 26:355-363.
5. Yebra-Pimentel E, Giraldez MJ, Glez-Mejome JM, et al. Variacion de la ratio longitud axial/radio corneal (LA/CR) con el estado refractivo ocular. Relacion con los componentes oculares. *Arch Soc Esp Oftalmol* 2004; 79: 317-324.
6. Bron AJ, et al. *Wolff's Anatomy of the Eye and Orbit*, 8th ed. Arnold Publishing, 1997; 211-214.
7. Sayegh FN. The correlation of corneal refractive power, axial length, and the refractive power of the emmetropizing intraocular lens in cataractous eyes. *Ger J Ophthalmol* 1996; 5: 328-331.
8. Raj PS, Ilango B, Watson A. Measurement of axial length in the calculation of intraocular-lens power. *Eye* 1998; 12: 227-229.

ORIGINAL ARTICLE

Harvey S. Uy, MD
Prospero Ma. C. Tũaño, MD

*Department of Ophthalmology
and Visual Sciences
University of the Philippines
Philippine General Hospital
Manila, Philippines*

Preseptal and orbital cellulitis at the Philippine General Hospital

ABSTRACT

Objective

To describe the clinical features, causative agents, management practices, and outcomes of preseptal and orbital cellulitis at a tertiary-care center in a developing country.

Methods

This is a retrospective case series of preseptal and orbital cellulitis seen at the Orbit Clinic of the Philippine General Hospital from January 1990 to December 1995. The medical records were reviewed and the following data obtained: age, gender, manner of disease presentation, causative agent, medical interventions, and outcomes.

Results

Fifty-six patients with preseptal cellulitis and 35 with orbital cellulitis were identified. Among the patients with preseptal cellulitis, the mean age at presentation was 12.6 ± 17.0 years. No gender predilection was observed. The most common presenting signs were lid swelling (all patients), eye redness (34%), fever (29%), and eye discharge (27%). Bilateral involvement occurred in 9 patients. Among those with orbital cellulitis, 25 were classified as orbital cellulitis, 5 as orbital abscess, and 5 as cavernous sinus thrombosis. There were slightly more females than males (1.3:1). The mean age at presentation was 17.1 ± 18.6 years. The most common symptoms were lid swelling (94%), ophthalmoplegia (89%), chemosis (77 percent), proptosis (71%), and decreased vision (51%). Both conditions were associated with antecedent infectious conditions such as skin and lid infection, sinusitis, dental abscess, respiratory-tract infection, and trauma. *Staphylococcus* was the most common organism isolated.

The most common initial antibiotics used were beta-lactamase-resistant penicillins. Other antibiotics were added based on clinical response and microbial studies. Orbital cellulitis was associated with sight threatening complications such as glaucoma, retinal vascular occlusion, exposure keratitis, and optic-nerve compression.

Conclusions

The etiology of preseptal and orbital cellulitis in this series differs from that in developed countries. Preseptal and orbital cellulitis should be distinguished early so that proper management can be instituted. Orbital cellulitis is associated with greater mortality and morbidity. CT scan and microbial studies are invaluable for appropriate diagnosis and management of orbital cellulitis.

Keywords: *Preseptal, Orbital, Postseptal, Cellulitis*

Correspondence to
Harvey S. Uy, MD
Asian Eye Institute
9F Phinma Plaza Building
Rockwell Center
1200 Makati, Philippines
Tel: +63-2-8982020
Fax: +63-2-8982002
Email: harveyuy@yahoo.com

The authors have no proprietary or financial interest in any product used or cited in this study.

PHILIPP J OPHTHALMOL 2005; 30(1): 28-33

© PHILIPPINE ACADEMY OF OPHTHALMOLOGY

PRESEPTAL and orbital cellulitis are potentially life- and sight-threatening periocular infections with varied etiologies and severity.¹ In the preantibiotic era, the complications of these infectious conditions such, as meningitis, brain abscess, and cavernous sinus thrombosis, resulted in high rates of mortality and blindness.² Prevention of these complications requires appropriate and timely antimicrobial intervention. Aggressive organisms such as *Haemophilus sp.* were classically taught to be the primary causes of periocular cellulitis in children; however, the introduction of vaccines for *Haemophilus influenzae* may have resulted in changing microbiologic spectrum of preseptal and orbital cellulitis.³

Most of the published reports on preseptal and orbital cellulitis involve populations in developed countries.²⁻⁹ This study investigated the clinical patterns, causative agents, management practices, and outcomes of preseptal and orbital cellulitis in a developing country like the Philippines.

METHODOLOGY

The medical records of all consecutive preseptal- and orbital-cellulitis patients seen at the Orbit Clinic of the Philippine General Hospital from January 1990 to December 1995 were identified and retrieved. The patient charts were reviewed and the following data obtained: age, gender, presenting signs and symptoms, results of imaging studies such as computerized axial tomography (CAT scan), results of microbial investigation such as blood and tissue aspirate cultures, type of medical intervention, and outcomes.

Table 1. Distribution of patients according to site of involvement and age at presentation.

Chandler Classification	Number of Patients	%	Mean Age (Years)	Male:Female Ratio
Preseptal cellulitis	56	62	12.6	26:30
Orbital cellulitis	25	28	17.7	11:14
Subperiosteal abscess	0	0	NA	0:0
Orbital abscess	5	5	16.0	2:3
Cavernous sinus thrombosis	5	5	15.2	2:3

Table 2. Presenting signs of preseptal cellulitis.

Presenting Signs	Number of Patients	Percent
Lid swelling/redness	56	100
Eye redness	19	34
Fever	16	29
Eye discharge	15	27
Lid tenderness	12	21
Blurring of vision	1	2
Bilaterality	9	16

Based on clinical findings and imaging studies, the patients were classified according to the scheme developed by Chandler:

- Group 1: Preseptal cellulitis (PC) – edema and inflammation confined to lid soft tissues.
- Group 2: Orbital cellulitis (OC) – true bacterial and leucocytic infiltration of orbital tissues with erythema, chemosis, eye pain, proptosis, limitation of eye movement, or some blurring of vision.
- Group 3: Subperiosteal abscess (SA) – collection of pus between the bony wall of the orbit and the periorbita.
- Group 4: Orbital abscess (OA) – collection of pus within the orbital soft tissue with marked exophthalmos, chemosis, severe impairment of vision, and ophthalmoplegia.
- Group 5: Cavernous sinus thrombosis (CST) – extension of migratory phlebitis into the cavernous sinus causing neurologic deficits and bilateral involvement.

RESULTS

Ninety-one patients presented with periocular infection. The distribution of patients according to the classification scheme of Chandler is presented in Table 1.

Preseptal Cellulitis (Group 1)

Fifty-six patients were diagnosed to have preseptal cellulitis (Group 1). The mean age at presentation was 12.6 ± 17.0 years (range, 0.1 to 65) and the median age was 4 years. No gender predilection was observed. The most common presenting signs of preseptal cellulitis are presented in Table 2. Bilateral involvement occurred in 9 of 56 patients (16%). Associated factors were identified in 48 of 56 (86%) patients (Table 3). The most common associated factors were lid infections and periocular trauma, which included eyelid abrasions, blunt trauma, dog bites, and one case of subgaleal hematoma. Nasolacrimal-duct obstruction was diagnosed in 10 of 56 (18%) patients.

Microbial studies were performed for 5 of 56 (9%) patients. In 4 patients, samples were obtained from conjunctival discharge or from lid-abscess material while

Table 3. Associated factors for preseptal cellulitis.

Associated Factors	Number of Patients	Percent
Lid infection	15	27
Lid trauma	13	23
Lacrimal-duct obstruction	10	18
Dentoalveolar abscess	5	9
Respiratory-tract infection	4	7
Sinusitis	1	2
Ear infection	1	2
Subdural hematoma	1	2
None	8	14

in one patient, blood was drawn and sent for culture and sensitivity studies. The conjunctival discharge established one case each of *Staphylococcus aureus* and gonococcal conjunctivitis that resulted in preseptal cellulitis. The rest of the samples resulted in negative cultures probably due to antibiotic treatment before consultation at our clinic. Because only a small number of patients underwent microbial studies, no conclusions can be made regarding the etiology of preseptal cellulitis.

Imaging studies were performed in only 3 patients with a history of head trauma and sinusitis. Thirteen patients were admitted because of severe eyelid swelling that prevented a full ocular examination.

Antibiotics were administered to all patients. Fifty-one of 56 (91%) patients were treated empirically with antibiotics. An intravenous loading dose was started in 46 of 56 (82%) patients. Cloxacillin or oxacillin was the preferred initial antibiotic (Table 4). In case of hypersensitivity to cloxacillin or oxacillin, cefazolin was administered because this drug has good coverage for *Staphylococci*. One patient with gonococcal conjunctivitis was given an intramuscular injection of ceftriaxone. Clindamycin was administered to one patient with maxillary sinusitis. In general, multiple antibiotics were started in patients with abscess formation or lid injury. Amoxicillin with clavulanic acid was administered to one patient who did not respond to penicillin.

A surgical procedure was performed in 20 of 56 (36%) patients. Fifteen (27%) patients underwent incision and drainage of a preseptal or lid abscess, 4 (7%) underwent dental extraction, and one patient (2%) underwent evacuation of an associated subdural hematoma.

All patients had improved at the time of discharge from the hospital. No complications were noted. None of the cases progressed to orbital cellulitis. Follow-up period ranged from one to two weeks. The short follow-up period is attributed to the lack of patient compliance with the follow-up schedule.

Postseptal cellulitis (Groups 2-5)

Thirty-five patients were diagnosed to have OC or its sequelae, OA and CST. Of these, 25 (71%) were classified as OC, 5 (14%) as OA, and 5 (14%) as CST. No cases of SA were observed. There were slightly more females than males (1.3:1). The mean age at presentation was 17.1 ± 18.6 years (range 0.8 to 78). The median age was 10 years.

The most common signs and symptoms of OC, OA, and CST are presented in Table 5. Lid swelling, ophthalmoplegia, and chemosis were the most common presenting signs. Proptosis was present in 25 (71%) patients. Hertel's exophthalmometry showed an average increase of 5.4 mm (range 1 to 10) in globe protrusion. Funduscopy revealed 4 patients with papilledema and 1

patient each with disc pallor, central-retinal-artery occlusion, and central-retinal-vein occlusion. Afferent pupil defects were seen in 6 of 35 (17%) patients. Resistance to globe retrodisplacement was observed in 5 of 35 (14%) patients. This low incidence may be due to interobserver variations in the interpretation of this

Table 4. Antibiotic treatment patterns for preseptal cellulitis.

Antibiotic	Number of Patients	Percent
Cloxacillin/oxacillin	41	74
Cefazolin	2	3
Penicillin	1	2
Ceftriaxone	1	2
Amoxicillin with clavulanic acid	1	2
Clindamycin	1	2
Oxacillin + aminoglycoside (gentamicin or amikacin)	4	7
Oxacillin + Chloramphenicol	2	3
Clindamycin + chloramphenicol	1	2
Cloxacillin + gentamicin + metronidazole	2	3

Table 5. Presenting signs of orbital cellulitis, abscess, and cavernous sinus thrombosis.

Presenting Sign	Number of Patients	Percent
Lid swelling	33	94
Ophthalmoplegia	31	89
Chemosis	27	77
Proptosis	25	71
Decreased vision	18	51
Fever	16	46
Neurologic changes	10	29
Fundus changes	7	20
Afferent pupil defect	6	17
Resistance to retrodisplacement	5	14
Exposure keratopathy	4	11
Intraocular pressure rise	3	9

Table 6. Associated factors for orbital cellulitis, abscess, and cavernous sinus thrombosis.

Associated Factor	Number of Patients	Percent
Lid infection	13	37
Sinusitis	6	17
Dental abscess	5	14
Respiratory-tract infection	5	14
Trauma	5	14
Panophthalmitis	2	6
Systemic illness	2	6
None	8	14

subjective test. Five of 35 (14%) patients presented with no light perception. Four patients (11%) had exposure keratopathy.

Of 5 patients with OA, the average amount of proptosis was 8.0 mm (range 6 to 10). All CST patients presented with additional neurologic findings (behavioral changes, sensorial changes, neck rigidity, Babinski, headache, vomiting, and facial numbness).

Predisposing factors were identified in 32 of 35 (89%) patients. Five of 6 (80%) patients with sinusitis manifested with ethmoid sinus involvement, 4 (67%) manifested with maxillary sinus involvement, and 1 patient (17%) had frontal sinus involvement. Multiple sinus involvement was seen in one patient. Trauma was a predisposing factor in 5 of 35 (14%) patients. Trauma included dog bites, blast injury, and penetrating eye injury. Panophthalmitis developed in patients with blast injury and penetrating injury. One patient each had associated chickenpox and concurrent septic arthritis (Table 6).

Microbiological studies were done in 22 (63%) patients. Thirty-two samples were obtained, of which 17 (53%) yielded positive cultures. Orbital-abscess material yielded positive cultures in 9 of 13 (69%) patients while blood culture and sensitivity yielded 6 of 11 (54%) positive cultures. Isolates from culturing 3 conjunctival discharge specimen did not correlate with orbital-abscess aspirate or blood cultures. Cerebrospinal fluid and anterior chamber aspirates were negative (Table 7).

Radiologic studies were done in 16 patients (46%). CT scan was performed for 11 patients who manifested with neurological changes, severe proptosis, or marked visual loss. The scans revealed 3 patients with intraorbital-soft-tissue swelling, 5 with intraorbital abscesses, with extension of the abscess to the ethmoidal sinus in 1 patient and extension into the frontal lobe in 2 patients. Cerebral edema and cerebritis were seen in one CST patient who later expired from uncal herniation. Three of 8 (38%) who underwent orbital radiography demonstrated orbital soft-tissue densities or sinus haziness. Three patients underwent both CT scan and orbital radiography (Table 8).

All patients diagnosed with orbital cellulitis were admitted for intravenous antibiotic treatment. The mean length of hospitalization was 17 days (range 1 to 78). Factors that influenced the choice of initial antimicrobial treatment included severity of the disease and focus of infection. Monotherapy with cloxacillin was administered to 12 (33%) patients. The remaining two-thirds received combination therapy that usually included a beta-lactamase-resistant penicillin derivative, an aminoglycoside or cephalosporin, and an antianaerobic antibiotic. The choice of medication was modified either by results of culture and sensitivity testing or by clinical response. Five

out of 7 patients (71%) showed resistance to penicillin treatment (Table 9).

The most common surgical intervention was incision and drainage of orbital abscess, performed when the patient was unresponsive to medical therapy. Drainage of the orbital abscess resulted in immediate and dramatic

Table 7. Results of microbial cultures among patients with orbital cellulitis, abscess, and cavernous sinus thrombosis (n = 32).

Organism	Number of Positive Cultures	Percent
<i>Staphylococcus sp.</i>	11	34
<i>Alcaligenes sp.</i>	1	3
<i>Escherichia sp.</i>	1	3
<i>Enterococcus sp.</i>	1	3
<i>Peptococcus sp.</i>	1	3
<i>Serratia sp.</i>	1	3
<i>Streptococcus sp.</i>	1	3
No growth	15	48

Table 8. CT scan findings among patients with orbital cellulitis, abscess, and cavernous sinus thrombosis (n = 11)

CT Scan Findings	Number of Patients	Percent
Orbital abscess	4	36
Sinusitis	4	36
Orbital soft-tissue swelling	3	27
Frontal lobe abscess	2	18
Meningitis	2	18
Cavernous sinus enlargement	1	8
Cerebral edema	1	8

Table 9. Antibiotic treatment for orbital cellulitis, abscess, and cavernous sinus thrombosis (n = 35)

Antibiotic	Number of Patients	Percent
Cloxacillin	12	33
Penicillin + chloramphenicol	7	20
Cloxacillin + chloramphenicol	5	14
Cloxacillin + gentamicin	2	6
Cloxacillin + clindamycin	1	3
Cloxacillin + cotrimoxazole	1	3
Ampicillin + metronidazole	1	3
Nafcillin + ceftriaxone	1	3
Cloxacillin + gentamicin + chloramphenicol	1	3
Clindamycin + gentamicin + chloramphenicol	1	3
Cloxacillin + ceftazidime + metronidazole	1	3
Cephalexin + chloramphenicol + metronidazole	1	3
Nafcillin + ceftazidime + netilmicin + metronidazole	1	3

improvement of the patient's condition. Enucleation or evisceration was performed in patients with ruptured globe and subsequent panophthalmitis to remove the focus of infection. Ethmoidectomy and antrostomy were performed in 2 cases with chronic sinusitis. Patients with dentoalveolar abscesses were referred for either dental extraction or drainage of the abscess by the oral route. Tarsorrhaphy was performed in one case with exposure keratitis. Biopsy was performed in two cases where the initial impression was malignancy but later turned out to be an infectious abscess.

One patient, a 4-year-old male with a dentoalveolar abscess with secondary cavernous sinus thrombosis and cerebral edema, died from complications of orbital infection. This patient developed uncal herniation despite drainage of intracranial abscess and medical therapy.

Visual Outcomes

None of the patients with PC suffered loss of visual acuity. Among the patients with postseptal infection, 10 (29%) experienced deterioration in visual acuity to 20/200 or worse. Five of 25 (20%) of OC patients, 4 of 5 (80%) of patients with OA, and 1 of 5 (20%) patients with CST lost all light perception. Nine patients continued to experience poor visual acuity even after treatment, with 3 eventually undergoing enucleation or evisceration and 6 losing all light perception permanently. Only one initially with no light perception demonstrated improvement in vision and obtained a final visual acuity of counting fingers. Proptosis was the most frequent clinical finding related to loss of vision (Table 5). Of 10 patients that were blind, 8 manifested with proptosis while only 2 patients without proptosis became blind.

Complications

Five patients developed elevated IOP that was easily controlled with topical carbonic anhydrase inhibitors and beta-blockers. Central-retinal-artery occlusion developed in 1 patient while central-retinal-vein occlusion affected 2 patients. These vascular occlusive events resulted in diminished visual acuity. Optic atrophy was observed in 2 patients.

The neurologic complications included meningitis in 3 patients, brain-abscess formation in 2 patients, and uncal herniation in one patient that resulted in death. Residual neurologic deficits included ophthalmoplegia, facial anesthesia, and chronic papilledema.

DISCUSSION

PC and OC are two important infectious ophthalmic conditions. A Medline literature search revealed that most of the published articles on PC and OC are from developed countries. We conducted this study to determine the

patterns of PC and OC in the Philippines where environmental and health standards may differ significantly from those in developed countries. In this series, PC occurred more frequently than OC and predominantly affected infants and young children, which may be related to the children's relative lack of antibodies.⁵ OC affects older children and teenagers, occurs less frequently, but is a much more severe disease. These demographic data parallel published data from developed countries.^{5,10}

The most frequent signs of OC in this series were lid swelling, ophthalmoplegia, chemosis, proptosis, and decreased vision. Similarly, the Michigan study reported that the most frequent symptoms include lid swelling, proptosis, ophthalmoplegia, chemosis, and blurred vision. Limitation of ocular motility and proptosis are believed to be the most reliable signs of OC.^{11,12}

Skin, dental, and nasolacrimal infections were the predominant predisposing factors in this series in contrast to developed countries where trauma and respiratory-tract infections were the most important predisposing factors for preseptal cellulitis. These findings suggest that poor hygienic and dental care, as well as lack of access to medical care, can contribute to the development of PC. This series demonstrated concurrent skin infection (eg. eyelid infection from trauma, infected hordeolum, spread of other periorbital skin infection) as the most common predisposing factor, followed by sinusitis, trauma, dentoalveolar abscess, and respiratory-tract infection. In contrast, sinusitis, trauma, and systemic diseases like asthma and diabetes were the most common predisposing causes for OC in developed countries.¹² Hodges and Tabarra reported similar trends in 23 patients from Saudi Arabia where only 30% of OC was associated with sinusitis.⁹ Concurrent infectious conditions were the predominant predisposing factors for OC in our series. This is probably due to poorer standards of hygiene and health care. Often, a neglected insect bite or skin wound led to a fulminant infection that spread to preseptal and postseptal tissues.⁹

Microbial studies were not performed for most cases of PC; however, majority of patients responded to empirical treatment. Since PC is a fairly benign condition, there was enough time for modification of drug therapy. Because OC is associated with more serious sequelae such as death and neurologic or ocular damage, appropriate antibiotic treatment should be started earlier and guided by the results of microbial studies as much as possible. In this series, around half of samples were positive for the causative agent, which were obtained from skin or orbital abscesses, the surfaces of infected wounds, or blood cultures.

Staphylococcus sp. was the most common organism recovered from orbital or skin abscesses and infected wounds among patients with PC and OC. Other isolated

microbes included anaerobes, *Streptococcus*, *Escherichia*, *Neisseria*, and *Serratia sp.* Weiss et al. reported *Staphylococci* as the most common organisms isolated in acute bacterial infections.⁵ Interestingly, *Haemophilus*, which is a common organism isolated in studies from developed countries, was not isolated in this series. Skin infections tended to be associated with *Staphylococci* and *Streptococci* while sinusitis and dental infections tended to be associated with mixed infections consisting of gram-negative and anaerobic bacteria.

Radiological studies were not contributory to PC management because only a few were requested, but were very useful for the management of OC. In particular, CT scans confirmed the presence of sinusitis, orbital abscesses, and intracranial involvement and identified patients who needed aggressive intervention such as drainage of orbital and brain abscesses, anticoagulant therapy for CST, and selection of antibiotics with good brain-barrier penetration.

Timely and appropriate antibiotic therapy is the most important component in the management of orbital infections. Empirical therapy should immediately be started after microbial specimens are obtained. Antibiotic selection may be guided by the foci of infection and disease severity. Patients with previous skin infections, trauma, or dacryocystitis usually received a beta-lactamase-resistant drug such as oxacillin, cloxacillin, or nafcillin. An intravenous loading dose may be given for more severe cases. Cephalosporin or amoxicillin with clavulanic acid is an alternative initial therapy. The UP-PGH infectious-disease service recommends intramuscular ceftriaxone for cases with associated gonorrheal conjunctivitis. Patients with associated dentoalveolar abscesses or ear infections receive an additional aminoglycoside or chloramphenicol in order to cover for gram-negative organisms. Clindamycin or metronidazole is started when an anaerobic infection is suspected.¹³ The choice of antibiotics should be guided by culture and sensitivity results and clinical response. Lack of improvement or deterioration within 2 to 3 days should prompt modification of antibiotic treatment.

Surgical intervention has an important role in the management of PC and OC. For patients presenting with toothaches, maxillary or mandibular swelling and tenderness, a dental evaluation can determine presence of dentoalveolar infections. Patients with otitis should be evaluated and treated by an otorhinolaryngologist. Orbital decompression is indicated for patients with impending visual loss, severe proptosis, glaucoma, or retinal vascular occlusion. Drainage of a localized infection such as orbital, dental, sinus, or intracranial abscesses or enucleation for endophthalmitis may remove foci of infection and lead to dramatic improvement of the clinical course. Biopsy may help distinguish an infectious from malignant process. Tarsorrhaphy may be useful for preventing exposure keratitis in cases where orbital pressure has normalized or where the primary goal is preservation of the ocular surface because of little visual potential.

In summary, OC is associated with greater morbidity and mortality and should be treated early and aggressively. The proper use of imaging and antimicrobial studies can greatly guide appropriate therapy.

References

1. Westfall CT, Baker AS, Shore JW. Infectious diseases of the orbit. In: Albert DM, Jakobiec FA, eds. *Principles and Practice of Ophthalmology*. Philadelphia: W.B. Saunders, 2000: 3121-3129.
2. Gamble RC. Acute inflammations of the orbit in children. *Arch Ophthalmol* 1933; 10: 483-497.
3. Donahue SP, Schwartz G. Preseptal and orbital cellulitis in childhood. *Ophthalmology* 1998; 105: 1902-1906.
4. Smith TF, O'Day D, Wright PF. Clinical implications of preseptal (peri-orbital) cellulitis in childhood. *Pediatrics* 1978; 62: 1006-1009.
5. Weiss A, Friendly D, Eglin K, et al. Bacterial and orbital cellulitis in childhood. *Ophthalmology* 1983; 90: 195-203.
6. Bergin DJ, Wright J. Orbital cellulitis. *Br J Ophthalmol* 1986; 70: 174-178.
7. Harris GJ. Subperiosteal inflammation of the orbit: a bacteriological analysis of 17 cases. *Arch Ophthalmol* 1988; 106: 947-952.
8. Clary R, Weber AL, Eavey R, Oot RF. Orbital cellulitis with abscess formation caused by sinusitis. *Ann Otol Rhinol Laryngol*. 1988; 97: 211-212.
9. Hodges E, Tabbara KF. Orbital cellulitis: Review of 23 cases from Saudi Arabia. *Br J Ophthalmol* 1989; 73: 205-208.
10. Spires JR, Smith RJ. Bacterial infections of the orbital and periorbital soft tissues in children. *Laryngoscope* 1986; 96: 763-767.
11. Rubin SE, Slavin ML, Rubin LG. Eyelid swelling and erythema as the only signs of subperiosteal abscess. *Ophthalmology* 1983; 90: 195-203.
12. Jackson K, Baker SR. Clinical implications of orbital cellulitis. *Laryngoscope* 1986; 96: 568-574.
13. Valenton MJ, Dy-liacco JU, Espiritu CG. Corneal and external-eye-disease problems in the Philippines. *Phillip J Ophthalmol* 1993; 22: 52-55.

ORIGINAL ARTICLE

Avelino L. Zapanta Jr., MD¹
Jerome S. Sarmiento, MD²
Carlos Alberto, MD²
Monserat A. Zapanta, MD¹

¹*Fatima Medical Center
Valenzuela City, Philippines*

²*St. Luke's Medical Center
Quezon City, Philippines*

Estimation of pupil size using a digital camera

ABSTRACT

Purpose

To compare pupil-size determination using a digital camera with the Rosenbaum-pupil-comparison and the millimeter-ruler methods.

Methods

The pupil size of 30 eyes of 15 medical students with a mean age of 27 years was measured by two examiners using a digital camera, Rosenbaum pupil comparison, and direct millimeter rule. Both examiners determined the mean pupil sizes for bright, dim, and dark settings.

Results

The mean pupil size as measured by both examiners at bright and dim light conditions was 5.6 mm (range 4.5 to 7.5) and 6.3 mm (range 4.5 to 8.0) respectively. The mean measurement for both examiners for dark is 7.0 (range 6.5 to 7.5). Only the digital camera was able to measure in dark setting with mean of 7.0 mm (range 6.5 to 7.5) for both examiners. Inter-examiner difference was lowest for the digital photography in all simulated settings.

Conclusion

The use of digital camera in determining pupil size was comparable to Rosenbaum chart and direct millimeter rule with lower inter-examiner differences.

Keywords: *Digital camera, Pupil size, Rosenbaum pupil comparison*

Correspondence to
Avelino L. Zapanta Jr., MD
Department of Ophthalmology
Fatima Medical Center
Marulas, Valenzuela City
1440 Philippines
Tel: +63-2-2932703
Fax: +63-2-2932705
E-mail: noyzmd@yahoo.com

The authors have no proprietary or financial interest in any product used or cited in this study.

PHILIPP J OPHTHALMOL 2005; 30(1): 34-36

© PHILIPPINE ACADEMY OF OPHTHALMOLOGY

PUPIL size is important in performing laser-assisted in situ keratomileusis (LASIK). It has been shown that patients with large pupils express dissatisfaction with their surgery.^{1,2} While most parameters measured before LASIK allow repeatable measurements with consistent results, pupil size has been the most difficult and inconsistent.³

Many devices have been developed for measuring pupil size, but these can be very expensive. One of these devices is an infrared video camera that can calculate the average pupil size of 10 pupil images captured in 2 seconds. It can measure the pupil in 3 adjustable light settings (bright, dim, very dark). The instrument is accurate up to ± 0.10 mm.⁴ Although accuracy and reliability are factors in choosing a device, one limiting factor that a clinician or center considers is cost. Currently, the Colvard infrared pupilometer is considered the gold standard for pupil measurement.¹

This paper introduces a method of pupil-size measurement using a digital camera. A study by Twa has shown that estimation of pupil size by digital photography, though not fast in getting a result, was repeatable and more accurate than estimates using other clinical methods.⁵

Unlike the Twa study, where a standard measurement (infrared video recorder) was assigned as reference and 4 other methods of measurements were used (ruler, semicircular templates, Colvard pupilometry, digital camera), this study had no standard reference and used only 3 methods. The three methods were treated equally.

METHODOLOGY

Fifteen volunteer medical students 23 to 36 years old (mean 27) with a pair of healthy eyes with normal pupil functions were enrolled in the study. Informed consent was taken. Excluded were those with history of eye trauma, intraocular surgery, and use of medicines (amphetamines, opiates) that could alter pupil function.

Each of the subjects underwent slit-lamp examination of the external and posterior part of the eye after which two examiners measured their pupil size. The digital photo measurements using a Sony DSC-P10 digital camera (Sony Electronics, Oradell, NJ, USA) were compared with the measurement taken with the use of Rosenbaum pupil-comparison gauge and direct millimeter rule.

The digital camera with 22 mm lens and 6.1x magnification was mounted on a tripod and placed 53 centimeters in front of the subject's eye. The subject was positioned with the chin resting on the slit-lamp table (the slit-lamp was removed for this purpose). The camera was set up to take photos of the right eye of all the subjects first, and then repositioned for the left eye. The digital camera was set to automatic flash. The camera's shutter

speed was fast enough to capture the image before the pupil could react to the flash. A light meter measured the change in the lighting condition inside the room (4 m x 4 m). One thousand lux was used for bright, 10 lux for dim, and < 1 lux for dark. Measurements in bright setting were done first, followed by dim, then dark. The subjects were allowed 5 minutes to adapt to each lighting condition.

To minimize accommodation, the subjects were asked to fixate at a target coming from a laser pointer at a distance of 4 m. A white ruler was placed just under the lower lid and included in the photo to serve as a gauge.

The photos were enlarged using Adobe Photoshop (Adobe Systems Inc., San Jose, CA, USA). A line was made from edge to edge of the pupil and the measurement was taken by comparing the length of the line to the ruler placed under the lid.

The size of each subject's pupils was estimated using the Rosenbaum chart. The chart was placed at the temporal side of each subject with the printed comparison gauge at the level of the cornea. The subject's pupil was compared with the different diameters from the gauge. This procedure was repeated for both eyes on all subjects. Half of a millimeter is added to the reading if the pupil diameter is in between two gauges.

The horizontal diameter of the pupils was also measured using a regular millimeter ruler. The ruler was placed immediately underneath the lower eyelids. This procedure was repeated for both eyes.

RESULTS

The mean pupil sizes in bright light were 5.68 mm for examiner I and 5.3 mm for examiner II using the Rosenbaum method, 6.0 mm for examiner I and 6.13 mm for examiner II using the millimeter rule, and 6.0 mm for examiner I and 5.9 mm for examiner II using the digital camera (Table 1).

In dim conditions, examiner I had a mean pupil-size estimation of 6.1 mm using the Rosenbaum, 6.6 mm with the millimeter rule, and 6.53 mm with the digital camera. Examiner II recorded it at 6.13 mm using the Rosenbaum, 6.58 mm with the millimeter rule, and 6.51 mm with the digital camera.

In dark conditions, the mean pupil size using the digital camera was 7.0 mm for examiner I and 7.03 mm for examiner II. Rosenbaum and millimeter rule could not be used.

Using F ratio as test statistic in determining the equality of means in ANOVA (analysis of variance), the mean pupil sizes using the three methods in bright and dim light conditions were equal. There was no difference in the measurements taken with the digital camera, Rosenbaum chart, and millimeter rule.

Table 1. Mean pupil measurements.

Lighting Condition	Rosenbaum		Millimeter Rule		Digital Camera	
	Examiner I	Examiner II	Examiner I	Examiner II	Examiner I	Examiner II
Bright	5.68	5.30	6.00	6.13	6.00	5.90
Dim	6.10	6.13	6.60	6.58	6.53	6.51
Dark	--	--	--	--	7.00	7.03

DISCUSSION

Digital photography method had larger estimates of pupil size in bright lighting, with a 0.46 mm difference from Rosenbaum and 0.12 mm from the millimeter rule methods. The differences were not statistically significant. In dim lighting, the millimeter rule method was 0.09 mm larger than digital photography while the Rosenbaum method had the lowest result.

The interexaminer-measurement difference for digital photography method was lowest in all simulated conditions, 0.1 mm for bright and 0.02 mm for dim. Rosenbaum had the highest interexaminer-measurement

difference at 0.38 mm for bright and 0.03 for dim. In dark setting where the examiners could no longer take measurements with either the Rosenbaum chart or millimeter ruler, the digital camera showed a 0.03 mm interexaminer-measurement difference.

The interexaminer bias was lowest for the digital camera due most likely to the stillness of the pupil during measurement. Other advantages include capability of measurements under dark conditions and easy storage of the digital images for future reference.

References

1. Probst, LE. The problem with pupils. *J Cataract Refract Surg* 2004; 30: 9-11.
2. Fan-Paul NI, Li J, Miller JS, Fiovakis, GJ. Night vision disturbances after corneal refractive surgery. *Surv Ophthalmol* 2002; 47: 533-546.
3. Chao B, Boxer Wachler BS. The role of pupil size in refractive surgery. <http://www.lasikinfocenter.net>. (accessed August 3, 2004).
4. Holladay JT. The High Cost of Inaccurate Pupillometry. <http://www.lasikinfocenter.net>. accessed August 3, 2004).
5. Twa MD, Bailey MD, Hayes J, Bullimore M. Estimation of pupil size by digital photography. *J Cataract Refract Surg* 2004; 30: 381-389.

Acknowledgment

The authors thank Dr. Imelda Garcia for her invaluable role in this study.

ORIGINAL ARTICLE

Harvey S. Uy, MD
Irene W. Tam, OD

*Asian Eye Institute
Makati, Philippines*

Patterns of uveitis in a Philippine eye clinic

ABSTRACT

Objective

To describe the distribution and clinical characteristics of endogenous uveitis among patients in a Philippine eye clinic.

Methods

The demographic and clinical data of 103 uveitis patients consulting at the Asian Eye Institute over an 18-month period were analyzed and compared with a previous report.

Results

The mean age at consultation was 43 ± 17 years (range 5 to 83). The male-to-female ratio was 1:1.3. The racial distribution consisted of Malay (77%), Chinese (22%), and Indian (1%). Forty-one patients (40%) presented with anterior uveitis, 15 (15%) with intermediate uveitis, 19 (18%) with posterior uveitis, and 28 (27%) with panuveitis. The most frequent diagnoses were idiopathic anterior uveitis (24%), pars planitis (14%), multifocal choroiditis and panuveitis (9%), Vogt-Koyanagi-Harada syndrome (9%), and Behcet's disease (8%). Long-term systemic therapy was needed for control of uveitis in 66 (64%) patients. Twenty patients (20%) developed sight-threatening ocular complications. Twelve patients (12%) with panuveitis became bilaterally blind.

Conclusions

The patterns of uveitis in the Philippines have markedly changed over the past 2 decades. Significant rates of ocular complications and blindness were found in this series, particularly among patients with panuveitis. These patients should be treated aggressively with corticosteroids and long-term immunosuppressive therapy.

Keywords: Uveitis, Philippines, epidemiology

Correspondence to
Harvey S. Uy, MD
Asian Eye Institute
9F Phinma Plaza Building
Rockwell Center
1200 Makati, Philippines
Tel: +63-2-38982020
Fax: +63-2-8982002
Email: harveyuy@yahoo.com

The authors have no proprietary or financial interest in any product used or cited in this study.

PHILIPP J OPHTHALMOL 2005; 30(1): 37-41

© PHILIPPINE ACADEMY OF OPHTHALMOLOGY

UVEITIS refers to a spectrum of intraocular inflammatory disorders affecting the uveal tract, retina, optic nerve, sclera, and lens. Endogenous uveitis refers to types of uveitis where the antigenic stimuli or source of inflammation originates from within the eye wall or enters the eye hematogenously. There are about 60 recognized uveitis entities, varying in distribution within a given population according to geographic, racial, genetic, and environmental factors.

The International Labor Organization reports that 8 million Filipinos work overseas, making the Philippines the largest supplier of migrant workers worldwide.^{1, 2} Because of the lack of published data on the patterns of endogenous uveitis among Filipinos, eye doctors in other countries who care for overseas Filipino workers afflicted with uveitis have limited sources of information to guide them in diagnosing and treating these patients. This situation prompted us to conduct this cross-sectional study using current classification systems and diagnostic techniques. The results of this study will update the clinical profile of Philippine uveitis patients and guide eye-care providers who serve the needs of this expanding migrant population.

METHODOLOGY

All endogenous uveitis patients consulting for the first time at the Asian Eye Institute (AEI) from January 1, 2003 to June 30, 2004 were included. AEI is a private multi-specialty ambulatory eye clinic whose primary catchment area is Metro Manila, a large urban center and home to 8 million people. Patients with traumatic uveitis, surgical uveitis and exogenous endophthalmitis were excluded except those with sympathetic ophthalmia. During the initial visit, a thorough ocular, medical, and family history was obtained and a standard uveitis questionnaire was administered as part of the review of systems. A comprehensive physical and ocular examination was conducted which included external eye examination, best-corrected Snellen visual acuity (BCVA), applanation tonometry, slit-lamp biomicroscopy, and dilated fundus examination.

Based on the patient's history, review of systems and clinical characteristics, a list of differential diagnosis was systematically generated and appropriate imaging and laboratory tests were requested using a targeted approach.^{3, 4} When indicated, the following diagnostic tests were performed: fluorescein angiography, indocyanine green angiography (ICG), B-Scan ultrasonography, optical coherence tomography, visual-field (VF) testing, and radiological studies such as radiography, computed tomography, or magnetic resonance imaging (MRI). Laboratory testing may have involved complete blood count, urinalysis, erythrocyte sedimentation rate, serum fluorescent treponemal antibody absorption detection

(FTA-ABS), human-leukocyte-antigen (HLA) typing, antinuclear antibodies, rheumatoid factor, liver-function tests, and serum antibody titers for *Toxoplasma gondii*, herpes simplex, and herpes zoster. Invasive tests may have involved biopsy of the skin, conjunctiva, sclera, aqueous, and vitreous. Culture and sensitivity and polymerase-chain-reaction studies were performed when indicated.

The anatomical sites of involvement were classified according to the International Uveitis Study Group (IUSG) system based on localization of the predominant site of intraocular inflammation.⁵ If the detailed history, review of systems, physical and ocular findings, and confirmatory laboratory test results pointed to a definite or highly probable etiological cause, a specific uveitis diagnosis was assigned and entered into the Registry. Otherwise the patient was classified as having idiopathic uveitis.

The patients were treated according to published guidelines for immunosuppressive drugs.⁶ Topical steroids dexamethasone, prednisolone acetate, or fluoromethalone were administered to all patients at doses one drop daily to one drop hourly based on the severity of the uveitis flare up. Local periocular triamcinolone acetonide injections (Kenalog, Bristol Myers, New York, NY, USA) were given for severe (+3 or +4 cells) uveitis and for cystoid macular edema. Systemic corticosteroids or immunosuppressive drugs were indicated in the presence of bilateral intermediate or posterior or panuveitis, sight-threatening uveitis, recurrent uveitis, and intolerance for topical or local steroid injections. If systemic drugs were administered for longer than 3 months in an effort to control ocular inflammation, the patient was classified as necessitating long-term systemic therapy (LST).

The last recorded BCVA was used to determine whether the patient was legally blind (20/200 or worse) in one or both eyes. The development of sight-threatening ocular complications such as cataract, glaucoma, retinal detachment, vitreous hemorrhage, and cystoid macular edema (CME) was also recorded. Glaucoma for this series was defined as elevated IOP (>25 mmHg) leading to visual-field and optic-nerve-head changes or necessitating at least 3 months of IOP-lowering medications.

Descriptive statistics are reported. The probability values for the comparison of percentage values were calculated using the chi square test with $p < 0.05$ considered significant. Data analysis was performed using Microsoft Excel 2000 version 9.0 (Microsoft Corporation, Redmond, WA, USA).

RESULTS

Of 12,250 new general-eye-clinic patients seen during the study period, 103 (0.84%) were diagnosed to have endogenous uveitis. Table 1 shows the demographic and clinical characteristics of the patients. The mean age at

presentation was 43 ± 17 years (range 5 to 83; median age = 40 years). The mean age at presentation was similar for all four groups when the patients were classified according to the predominant site of involvement. The male to female ratio was 1:1.3. No gender predominance was observed for anterior, intermediate, and panuveitis; however, more females than males had posterior uveitis. All 5 patients with retinal vasculitis were female.

Filipinos, who belong to the Malay race (77%), made up the predominant racial group, followed by Chinese (22%) and a single Indian patient (1%). Table 2 shows the sites of involvement according to racial group. Filipino

Table 1. Demographic data, clinical characteristics, use of systemic immunosuppressive medications, and sight-threatening complications according to site of involvement.

Criteria	Total (n = 103)	Anterior (n = 41)	Intermediate (n = 15)	Posterior (n = 19)	Panuveitis (n = 28)
Age (years)					
Range	5 - 83	11 - 77	18 - 73	5 - 76	20 - 83
Mean	43 ± 17	45 ± 17	38 ± 15	42 ± 21	41 ± 13
Sex					
Male	45	19	7	5	14
Female	58	22	7	15	14
M:F	1:1.3	1:1.2	1:1	1:3	1:1
Laterality					
Unilateral	45 (44)	27 (66)	4 (29)	10 (50)	4 (14)
Bilateral	58 (56)	14 (34)	10 (71)	10 (50)	24 (86)
Blindness					
Monocular	18 (18)	6 (15)	5 (36)	2 (10)	5 (18)
Binocular	12 (12)	0	0	0	12 (43)
Treatment					
Systemic immunosuppressive	66 (64)	15 (37)	12 (86)	14 (70)	25 (89)
Complications					
Cataract	35 (34)	13 (32)	7 (50)	0 (0)	15 (54)
Glaucoma	13 (13)	4 (7)	0 (0)	1 (5)	7 (25)
CME	11 (11)	3 (7)	3 (21)	3 (15)	2 (7)
RD	5 (5)	1 (2)	0 (0)	1 (5)	3 (11)
VH	4 (4)	0 (0)	1 (7)	1 (5)	1 (4)
Hypotony	1 (1)	0 (0)	1 (7)	0 (0)	0 (0)
Optic neuritis	1 (1)	0 (0)	0 (0)	1 (5)	0 (0)

Numbers in parenthesis indicate percentages based on (n) per column
 CME - cystoid macular edema
 RD - retinal detachment
 VH - vitreous hemorrhage

Table 2. Anatomical site of involvement distributed according to race.

Site	Filipino (n = 78)	Chinese (n = 24)	Indian (n = 1)
Anterior	24 (31)	16 (67)	1 (100)
Intermediate	14 (18)	1 (4)	0 (0)
Posterior	15 (19)	4 (17)	0 (0)
Panuveitis	25 (32)	3 (12)	0 (0)

patients developed uveitis in all sites of involvement but were particularly prone to develop anterior and panuveitis. The most common diagnoses among Filipinos were: idiopathic anterior uveitis, idiopathic pars planitis, Vogt-Koyanagi-Harada syndrome (VKH), Behcet's disease, and multifocal choroiditis and panuveitis (MCP). The predominant type by site of involvement among Chinese patients was anterior uveitis. The most common diagnoses among Chinese were: idiopathic anterior uveitis, HLA-B27-associated uveitis, MCP, and retinal vasculitis. Only one Chinese patient presented with intermediate uveitis; none developed VKH or Behcet's disease.

Anterior uveitis was the most common (40%), followed by panuveitis (27%), posterior uveitis (19%), and intermediate uveitis (14%). A specific diagnosis was established in 61 (59%) patients. The rest were diagnosed as having idiopathic uveitis. The most frequent specific descriptive disease entities were: multifocal choroiditis and panuveitis (MCP) (9%), Vogt-Koyanagi-Harada (VKH) syndrome (9%), Behcet's disease (8%), HLA B27-associated uveitis (5%), and serpiginous choroidopathy (4%). Idiopathic anterior uveitis (IAU) was diagnosed in 25 (24%), idiopathic intermediate uveitis in 14 (14%), and idiopathic retinal vasculitis in 3 (3%) patients (Table 3).

An infectious etiology was identified in 9 (9%) patients while the rest presented with noninfectious autoimmune

Table 3. Frequency of specific uveitis etiologies or diagnoses.

Anatomical Site	Specific Diagnosis	Number of Patients	Percent
Anterior	Idiopathic	25	24
	HLA B27 positive	5	5
	Juvenile rheumatoid arthritis	3	3
	Sclerouveitis	3	3
	Ankylosing spondylitis	1	1
	Fuch's heterochromic	1	1
	Herpes simplex	1	1
	Leprosy	1	1
	Psoriatic arthritis	1	1
Intermediate	Idiopathic	14	14
	Multiple sclerosis	1	1
Posterior	Serpiginous choroidopathy	4	4
	Idiopathic retinal vasculitis	3	3
	Toxocara	3	3
	Toxoplasma	3	3
	Multiple evanescent white-dot syndrome	2	2
	Systemic lupus erythematosus	2	2
	Frosted branch	1	1
Panuveitis	Punctate inner choroidopathy	1	1
	Multifocal choroiditis and panuveitis	9	9
	Vogt-Koyanagi-Harada	9	9
	Behcet	8	8
	Sympathetic ophthalmia	1	1
	Tuberculosis	1	1

uveitis. Among the infectious causes of uveitis, *Toxocara* and *Toxoplasma* were the most common identifiable etiologic agents (3 each) followed by one case each of herpes simplex, leprosy, and tuberculosis. None of the 32 patients tested for FTA-ABS were positive.

Most patients (56%) experienced bilateral involvement. The number of eyes involved was affected by the site of involvement ($p < 0.001$). Bilateral involvement occurred less frequently among patients with anterior uveitis (34%) and more frequently among patients with intermediate (71%) and panuveitis (86%). For posterior uveitis, an equal number of patients experienced unilateral and bilateral involvement. Forty-two of 158 involved eyes had severely decreased BCVA of 20/200 or worse. Eighteen patients (18%) were blind in one eye while 12 (12%) were blind in both eyes. Only patients with panuveitis developed bilateral blindness.

Systemic immunosuppressive drugs were required for control of intraocular inflammation in 66 (64%) patients (Table 1). Systemic medications were administered for most patients with intermediate, posterior, and panuveitis. Only a third of patients with anterior uveitis needed systemic medication. The most common agents used were oral nonsteroidal antiinflammatory agents (celecoxib, valdecoxib, mefenamic acid, diclofenac sodium), corticosteroids, methotrexate, and pulse intravenous cyclophosphamide.

Forty-seven of 103 (46%) patients developed sight-threatening complications. Cataract formation (34%) was the most frequent sight-threatening complication, except in patients with posterior uveitis. Thirteen patients developed glaucoma (13%) in the whole sample population. However, the patients with intermediate uveitis were spared from developing glaucoma. CME developed in 11 patients (11%). Less frequent complications included

retinal detachment, vitreous hemorrhage, hypotony, and optic neuritis (Table 1).

DISCUSSION

The distribution of uveitis differs according to geographic, genetic, and environmental factors. As in published reports, the age at presentation to the clinic occurs in the third or fourth decade in this series.⁷⁻¹⁰ Because the Philippines has a young population, the number of uveitis cases is expected to increase over time as more children enter the third or fourth decade of life. Filipino patients with anterior uveitis tend to manifest unilateral involvement while patients with intermediate and panuveitis were more prone to experiencing bilateral involvement.

The patterns of uveitis in this series are markedly different from those of the 1978 series reported by Fajardo et al. (Table 4). Other studies have shown that patterns of uveitis in a certain geographic area change over time.^{8,10} In the 1978 series, the most frequent types of endogenous uveitis by cause were idiopathic, tuberculous, lens-induced, rheumatoid, and sympathetic ophthalmia. In this series, these were: idiopathic, MCP, VKH, Behcet's disease, and HLA B27-associated uveitis. The reduction in frequency of idiopathic cases from 53.8% in 1978 to 41% in 2004 is likely related to advances in the diagnostic technologies including PCR, antibody assays, genetic testing, MRI, VF, and ICG.

Improvements in the delivery of public-health services may have led to changes in uveitis patterns. Over the past 2 decades, government programs that provide free antituberculosis medicines may have led to decreasing frequency of tuberculous uveitis. The local detection rate of TB has improved from 10% in 1998 to 58% in 2002, and the treatment success rate from 84% to 88%.¹¹ The increasing availability of ophthalmic care as practising Filipino ophthalmologists grow in number, especially in highly populated urban centers, is a possible reason for the near disappearance of lens-induced uveitis and sympathetic ophthalmia. We cannot compare the frequencies of infectious endogenous uveitis (eg. *Toxocara*, *Toxoplasma*, Tuberculous) with other series because we did not screen all patients in this series for these diseases.

The evolution and acceptance of uveitis classification systems, diagnostic tests, and diagnostic criteria have led to higher recognition of specific disease entities like MCP, SLE, Behcet's disease, and the white-dot syndromes. For example, this study reveals that Behcet's disease and VKH are significant causes of uveitis in the Philippines. The frequency of rheumatoid-disease-related uveitis has remained essentially the same. The absence of human immunodeficiency (HIV) virus related ocular infections is likely to be multifactorial and may include a reluctance

Table 4. Changes in uveitis diagnoses.

2004 Series	%	1978 Series	%
Idiopathic	41	Idiopathic	53.8
MCP	9	Tuberculosis	16.7
VKH	9	Infection	10.6
Behcet	8	Lens induced	4.7
HLA B27 associated	5	Rheumatoid	4.3
Rheumatoid	3	VKH	2.5
Sclerouveitis	3	Sympathetic ophthalmia	2.7
Toxoplasma	3	Toxoplasma	1.4
Toxocara	3	Leprosy	0.9
White-dot syndrome	3	Herpes	0.8
SLE	2	Nematode	0.4

MCP - multifocal choroiditis and panuveitis
 VKH - Vogt-Koyanagi-Harada disease
 SLE - systemic lupus erythematosus

by patients to seek consultation, sequestration of HIV infected patients in specialized care centers, or short life expectancy.

Systemic immunosuppressive drugs were needed for control of intraocular inflammation in 2 of every 3 patients. The site of involvement greatly influenced the need for systemic therapy. Only 1 in 3 patients with anterior uveitis needed systemic medications while most patients with intermediate, posterior, and panuveitis needed systemic therapy. In our practice, topical or local corticosteroid injections were preferred for anterior uveitis patients with only unilateral involvement in order to avoid systemic side effects. Corticosteroids for local injection, such as triamcinolone acetonide, are now readily available in the Philippines and have been used with great efficacy by our service in the treatment of severe disease flare up and resolution of CME. Systemic therapy, including use of corticosteroids, was aggressively implemented for patients with intermediate, posterior and panuveitis especially when both eyes were involved. Steroid-sparing immunosuppressive drugs were given for recurrent or chronic cases of uveitis.

The most common sight-threatening complications were cataract, glaucoma, and CME. Anterior-uveitis patients mostly developed cataracts while intermediate-uveitis patients tended to develop cataracts and CME. None of the intermediate-uveitis patients developed glaucoma. None of the posterior-uveitis patients developed cataracts. Those with panuveitis, which has been associated with poorer visual outcomes in previous studies,¹² developed more severe ocular complications like glaucoma and retinal detachment. In this series, only panuveitis patients developed bilateral blindness. Because of the great risk for poor outcomes, we recommend that aggressive treatment with corticosteroids and immunosuppressive medications be started early for these patients.

Uveitis is a major cause of blindness worldwide. It has been estimated that uveitis accounts for 30,000 new cases or 10% of blindness in the United States annually.¹³ This study shows that many Filipino patients lose vision from uveitis. However, it does not estimate the socioeconomic and psychological costs of blindness among these young (<50 years) members of society.

This is a prospective clinic-based case series and its findings should be interpreted with caution. Clinic-based

studies provide dissimilar estimates of disease incidence, prevalence, or patterns of distribution as compared to community-based studies.¹⁴ A clinic-based study is subject to referral bias. Because the study site is a specialty eye-care center, the patients in this study probably suffer from more serious disease compared with the general population. Therefore, these patients are more likely to require systemic medications and develop more severe complications. Because the study site is in an urban center, the results and recommendations are not applicable to a rural setting. Nevertheless, in the absence of recent community or clinic-based studies, this study may provide the best representation of the current patterns of uveitis in the Philippines.

In summary, this study demonstrated the changing disease patterns of uveitis in a Philippine urban center. We have also shown that significant rates of ocular complications and blindness occur among Filipino uveitis patients. We recommend that aggressive ocular and systemic therapy be given for patients with panuveitis who are at great risk for developing binocular blindness.

References

1. Albuero FA, Abella DI. Skilled labor migration from developing countries: Study on the Philippines. International Migration Papers No. 51. July, 2002. International Labor Office.
2. Wehrfritz G, Vitug M. Philippines: Workers for the World. <http://www.msnbc.msn.com/id/6100244/site/newsweek> (accessed October 20, 2004).
3. Nussenblatt RB, Whitcup SM, Palestine AG. *Uveitis: Fundamentals and Clinical Practice*. 2nd ed. Missouri: Mosby-Year Book, 1996: 373-375.
4. Harper SL, Chorich LJ III, Foster CS. Diagnosis of uveitis. In: Foster CS, Vitale AT, eds. *Diagnosis and Treatment of Uveitis*. Philadelphia: WB Saunders Company, 2002, chap. 6: 79-103.
5. Bloch-Michel E, Nussenblatt RB. International Uveitis Study Group recommendations for the evaluation of intraocular inflammatory disease. *Am J Ophthalmol* 1987; 103: 234-235.
6. Jabs DA, Rosenbaum JT, Foster CS, et al. Guidelines for the use of immunosuppressive drugs in patients with ocular inflammatory disorders: recommendations of an expert panel. *Am J Ophthalmol* 2000; 130: 492-513.
7. Rodriguez A, Calonge M, Pedroza-Seres M, et al. Referral patterns of uveitis in a tertiary-care center. *Arch Ophthalmol* 1996; 114: 593-599.
8. Pivetti-Pezzi P, Accorinti M, La Cava M, et al. Endogenous uveitis: An analysis of 1,417 cases. *Ophthalmologica* 1996; 210: 234-238.
9. Dandona L, Dandona R, John RK, et al. Population-based assessment of uveitis in an urban population in southern India. *Br J Ophthalmol* 2000; 84: 706-709.
10. Wakabayashi T, Morimura Y, Miyamoto Y, Okada AA. Changing patterns of intraocular inflammatory disease in Japan. *Ocular Immunol Inflamm* 2003; 11: 277-286.
11. USAID. Infectious diseases: Philippines. http://www.usaid.gov/our_work/global_health/id/tuberculosis/countries/ane/Philippines_profile (accessed May 14, 2005).
12. Durrani OM, Tehrani NN, Marr JE, et al. Degree, duration, and causes of visual loss in uveitis. *Br J Ophthalmol* 2004; 88: 1159-1162.
13. Nussenblatt RB. The natural history of uveitis. *Int Ophthalmol* 1990; 14: 303-308.
14. Gritz DC, Wong IG. Incidence and prevalence of uveitis in Northern California. *Ophthalmology* 2004; 111: 491-500.

INSTRUCTIONS TO AUTHORS

SUBMISSION

The PHILIPPINE JOURNAL OF OPHTHALMOLOGY adheres to the policies set forth in the "Uniform Requirements for Manuscripts Submitted to Biomedical Journals" written by the International Committee of Medical Journal Editors (*N Engl J Med* 1997; 336:309-314).

The journal publishes articles in the following categories:

- Original Articles, including clinical or laboratory investigations, clinical epidemiology, and evaluation of diagnostic and surgical techniques
- Evidence-Based Medicine (EBM), including systematic review and metaanalysis
- Lectures and Symposiums
- Case Reports and Case Series
- Brief Reports
- Special Matters

Letters, correspondence, and guest editorials may also be published.

Manuscripts submitted to the journal must be original material that has not been published or accepted for publication elsewhere. All papers are submitted to a panel of experts for peer review. Manuscripts may be sent to:

Editor in Chief
Philippine Journal of Ophthalmology
Unit 815 Medical Plaza Makati
Amorsolo Street, corner Dela Rosa Street
1229 Makati City, Metro Manila
Philippines

Other Contact Details

Phone: +63-2-8135324
Fax: +63-2-8135331
E-mail: pjo@pao.org.ph

MANUSCRIPT PREPARATION

Submitted manuscripts should not exceed 18 double-spaced typewritten pages (paper size 8.5 x 11 inches), including references, legends, tables, and figures (approximately 6-7 published pages). Use Times New Roman font size 12. Submit 3 hard copies of the manuscript and a digital copy in a compact disc (CD-ROM) or 3 .5 floppy diskette. Manuscripts should begin each component on a new page and be in the following order: (1) title page, (2) abstract, (3) text, (4) acknowledgments, (5) references, (6) legends for tables/figures, (7) tables, (8) figures (photographs, illustrations and graphs). A copyright transfer form with original signature and transmittal letter should accompany the manuscript.

TITLE PAGE

The title page should include:

1. Title of the article which should be informative, concise, meaningful, as brief as possible, and no longer than 135 characters.
2. Name of each author with his or her highest academic degree(s) and complete address of institutional affiliation.
3. Financial support, if any. Provide the agency name and city, company name and city, fellowship name, and grant number.
4. Proprietary interest statement. Each author is expected to disclose any type of financial interest related to the manuscript, including stock or ownership of a business entity connected to a product described in the paper, paid consulting for the company or competing companies, travel support or patent rights to a drug or piece of equipment.
5. List of any meeting(s) where the material is under consideration for presentation or has been previously presented. Indicate name, place, month, and year of the meeting.
6. Corresponding author's name, mailing address, telephone, fax, and e-mail address. The corresponding author will be responsible for all questions about the manuscript and for reprint requests. Only one author is to be designated corresponding author and he/she does not need to be the first author on the manuscript.
7. Appropriate footnotes.
8. Five keywords.

ABSTRACT

Provide a structured abstract of 300 words or less with the following four headings:

Objective: State the purpose or objective of the study.

Methods: The following must be included:

- Study Design: Identify the study design using a phrase such as randomized or nonrandomized clinical trial, case-control study, cross-sectional study, cohort study, case series, case report, systematic review, meta-analysis, review, experimental study, or historical manuscript. Additional modifiers can be included (consecutive, retrospective, prospective, observational, interventional, nonconsecutive, etc).
- Setting: Such as multicenter, institutional, clinical practice, etc.
- Participants, Patients or Study Population: Number of patients/eyes, selection procedures, inclusion/

clusion criteria, randomization procedure, and masking.

- Intervention or Observation Procedure(s)
- Main Outcome Measure(s)
- Data and Statistical Analyses

Results: Briefly summarize the principal outcome measurements/data obtained. Results should be accompanied by data with confidence intervals and the exact level of statistical significance.

Conclusions: Provide brief and concise conclusion(s) directly supported by the data.

TEXT

Number the pages of the manuscript consecutively, beginning with the title page as page one. The text should, in general, not exceed 18 double-spaced typewritten pages.

Organize and prepare the manuscript to include the following sections:

Introduction: The Introduction, without a heading, should refer only to the most pertinent past publications and should not be an extensive review of the literature. Include a brief background, the research question and/or rationale, objectives/purposes of the study, and major hypothesis to be tested, if any.

Methods: Methods should be written with sufficient detail to permit others to duplicate the work. The following should be included:

- Study Design: Identifies the study design using a phrase such as randomized or nonrandomized clinical trial, case-control study, cross-sectional study, cohort study, case series, case report, systematic review, metaanalysis, review, experimental study, or historical manuscript. Additional modifiers may be included (e.g. consecutive, nonconsecutive, retrospective, prospective, observational, interventional).
- Setting: (e.g. multicenter, institutional, clinical practice)
- Participants, Patients, or Study Population: Number of patients/eyes, selection procedures, inclusion/exclusion criteria, randomization procedure, and masking.
- Intervention or observation procedure(s)
- Main and secondary outcome measure(s)
- Data and statistical analyses.

For clinical studies, statements regarding adherence to the Declaration of Helsinki, approval by Institutional Review Board (IRB)/Ethics Committee, and description of the informed consent process should be included. For

animal research, the Association for Research in Vision and Ophthalmology (ARVO) guidelines for animal research should be followed and adherence to the said guidelines should be stated. Previously published procedures should be identified by reference only.

Results: Results must be concise. Provide demographic data of the study population. Describe outcomes and measurements in an objective sequence with minimum discussion. Data should be accompanied by confidence intervals (usually at the 95% interval) and exact *p* values or other indications of statistical significance.

Discussion: The Discussion should be restricted to the significant findings presented. Avoid excessive generalization and undue speculation. Digressions and theorizing are not appropriate. Elucidate on (but do not reiterate) the results, provide responses to other and contradictory literature, identify limitations or qualifications of the study, and state the conclusions that are directly supported by the data. Give equal emphasis to positive and negative findings, whether and what additional study is required, and conclude with the clinical applications or implications supported by the study. The conclusion(s) is (are) incorporated into the end of the discussion and should be directly supported by the results. Authors should avoid making statements on economic benefits and costs unless their manuscript includes economic data and analyses. Avoid claiming priority of the content unless you provide the literature search protocol used.

BRIEF REPORTS

A brief report is an original contribution (generally an interesting case, a case series, surgical technique, or experimental study) with a concise message. Manuscript must adhere to the PJO format guidelines, except that the abstract should contain no more than 150 words and the body no more than 1,000 words. References should be limited to 5.

ACKNOWLEDGMENTS

Acknowledge statistical consultation and assistance (when provided by someone other than an author) in an acknowledgment at the end of the article, before the references. Include the name, degree, and affiliation of the individual. Consultants (other than statistical consultants), editorial assistants, photographers, artists, laboratory associates, and others who assist in preparation of a manuscript are not to be acknowledged, however valuable their service.

Because readers may infer their endorsement of the data and conclusions, all persons acknowledged must have given permission to be acknowledged and this must be confirmed in the cover letter.

APPENDIX

An appendix should be used very sparingly. However, it is appropriate to provide survey forms, to list the members of a study group, or explain complex formulas or information.

In studies involving a study group, the writing group authors should be listed along with the group name (e.g. Smith TT, Jones JJ on behalf of the Pediatric Amblyopia Study Group) on the title page. Other group members should be listed in an appendix. When the study group name alone is listed on the title page, the Copyright Transfer Agreement requires only the original signature of the Corresponding Author. When a series of authors is listed on the title page in conjunction with the study group name, the Copyright Transfer Agreement must include the original signatures of these authors.

REFERENCES

List only references that are pertinent to the manuscript. Cite only published studies as references. Cite/Quote from the entire study, not the abstract. You may acknowledge “unpublished data” or submitted articles within parentheses in the text. Reference to a “personal communication” within parentheses in the text must be accompanied by a signed permission letter from the individual being cited.

References should be numbered consecutively in the text and in the reference list. In the text, reference numbers are entered as superscripts. The references must be verified by the author(s) against the original documents. PubMed (<http://www.ncbi.nlm.nih.gov>) offers a useful reference checker. References to journal articles should include: the author or authors (for more than four authors, list only the first three followed by “et al.”), title, journal name (as abbreviated in Index Medicus), year, volume number, and inclusive page numbers.

References to books should include: the author or authors, chapter title (if any), editor or editors (if any), book title, edition (other than the first), city of publication, publisher, copyright year, and inclusive pages of the chapter or section cited.

Web site references must include author (or web site owner), title of article, date article was posted, publication (if applicable), complete web site address, and date accessed.

Examples

Journal Article (If four or fewer authors, list all)

Fishman GA, Alexander KR, Milam AH, Derlacki DJ. Acquired unilateral night blindness associated with a negative electroretinogram waveform. *Ophthalmology* 1996; 103: 96-104.

Journal Article (If five or more authors, list only the first three and add et al.)

Vail A, Gore SM, Bradley BA, et al. Clinical and surgical factors influencing corneal graft survival, visual acuity, and astigmatism. *Br J Ophthalmol* 1996; 103: 41-49.

Chapter in a Book

Parks MM, Mitchell PR. Cranial nerve palsies. In: Tasman W, Jaeger EA, eds. *Duane's Clinical Ophthalmology*, revised ed. Philadelphia: JB Lippincott, 1993; v. 1, chap. 19: 550-551.

Book

Miller NR. *Walsh and Hoyt's Clinical Neuro-Ophthalmology*, 4th ed. Vol. 4. Baltimore: Williams & Wilkins, 1991; 2102-2114.

Web site

World Health Organization. Hospital infection control guidelines for severe acute respiratory syndrome. April 16, 2003: <http://www.who.int/csr/sars/infectioncontrol/en> (accessed April 24, 2003).

TABLES

Tables should follow references. Each table must be titled and numbered consecutively using Arabic numbers as mentioned in text. The title should be brief and fully understandable without reference to the text. Each table column and row must have a heading. Tables that indicate the mean should have the corresponding standard deviation. Legends must identify all symbols that appear in the tables and graphs.

FIGURES (PHOTOGRAPHS, ILLUSTRATIONS, AND GRAPHS)

Submit three (3) identical complete sets of prints and a digital copy if available. Each print must be separately labeled with the author's name, figure number and an indication (arrow) as to orientation (up). Put all information on a separate label on the back of the illustration to avoid writing on or damage to the prints.

Prints of figures (clinical photographs, fluorescein angiograms, CT, MRI, X-ray, photomicrographs, TEM, SEM, graphs, etc.) must be large enough to be easily read, preferably 4 x 6 inches. The digital copy of each photograph or illustration should be saved in individual files in either TIF or JPEG format with a resolution of at least 300 dpi. Photographs and illustrations saved in “MS Power point” or “MS Word” format are not acceptable. Graphs may be submitted in “MS Power Point” or “MS Excel” format. Text in figures must not be smaller than 10 points when finally reproduced in the Journal.

Each figure must be numbered consecutively in Arabic numerals by order of citation in the text. Each should

have a brief explanatory legend. Legends must identify all symbols or letters that appear on the prints. Histologic figures, stains, and magnifications should be noted in the legend. Graphs that indicate the mean should include the standard deviation. Any figure that has been published elsewhere should have an acknowledgment to the original source. A copy of the release to publish the figure signed by the copyright holder must also be submitted.

Clinical photographs should be masked when possible to prevent identification of the patient. Clinical photographs that permit identification of an individual must be accompanied by a signed statement by the patient or guardian granting permission for publication of the pictures for educational purposes.

Color reproduction of figures will be published at the author's expense based on prevailing rates. Check with the PAO office for exact cost. If a manuscript has been reviewed and accepted with color photos, it must be published with color photos. The author may opt to have them printed in black and white at no expense. However, much of the information may be lost if photomicrographs or histological slides and specimen are printed in black and white.

ABBREVIATIONS

Restrict abbreviations to those that are widely used and understood. Avoid abbreviations that have meaning only in the context of your specific manuscript. If an abbreviation is to be used, it should appear in parentheses immediately after the term or phrase to which it refers when it is stated for the first time in the text.

INSTRUMENTS, DRUGS, AND MANUFACTURER NAMES

Use generic names only in the text body. State the trade name of a particular drug cited in parentheses including

manufacturer's name, city, state and/or country when first mentioned in the text. With regard to instruments utilized in the study, enclose in parentheses the specific model, manufacturer's name, city, state and/or country.

TRANSMITTAL LETTER

Each submission must be accompanied with a letter to the editor in chief. It must identify the corresponding author, list any meetings where the material is under consideration for presentation or has been previously presented and disclose any conflict of interest. The transmittal letter must include a copyright transfer. The editorial office must be supplied with phone and fax numbers for the corresponding and first author(s), and e-mail addresses, if available.

COPYRIGHT

Consideration of manuscripts for publication in the PHILIPPINE JOURNAL OF OPHTHALMOLOGY is dependent on the assurance that the material (in whole or part) is not under consideration by another journal, is not in press in any other format, and has not been previously published. Each author must sign a statement transferring copyright ownership to the Philippine Academy of Ophthalmology. Manuscripts which have been accepted for publication may be published in another journal after securing a written consent from the editor in chief of the PHILIPPINE JOURNAL OF OPHTHALMOLOGY.

These instructions may be downloaded from the PJO web site at www.pao.org.ph

COPYRIGHT TRANSFER

Title of Article

Authors

1. _____
2. _____
3. _____
4. _____
5. _____

In submitting the above-titled article, I/we hereby transfer, assign, or otherwise convey all copyright ownership to the Philippine Academy of Ophthalmology in the event that such work is published in the PHILIPPINE JOURNAL OF OPHTHALMOLOGY (PJO). Such conveyance covers any product, whether print or electronic, that may derive from the published journal. I/We affirm that this article has not been previously published in or submitted for publication to another journal, except under circumstances communicated to PJO in writing at the time the article was first submitted.

Each author must sign a Copyright Release form. The signatures need not appear on the same page. All manuscripts submitted become the property of the journal.

Name (print)	Proprietary or Financial Interest (Yes/No*)	Signature	Date
1. _____	_____	_____	_____
2. _____	_____	_____	_____
3. _____	_____	_____	_____
4. _____	_____	_____	_____
5. _____	_____	_____	_____

**If yes, please explain on the title sheet. See instructions to authors for details.*

Submit this signed transfer with your manuscript to:

The Editor in Chief
 Philippine Journal of Ophthalmology
 Unit 815 Medical Plaza Makati
 Amorsolo Street, corner Dela Rosa Street
 1229 Makati City, Metro Manila
 Philippines

Other Contact Details

Phone: +63-2-8135324
 Fax: +63-2-8135331
 E-mail: pjo@pao.org.ph

This form may be downloaded from the PJO web site at www.pao.org.ph