

ORIGINAL ARTICLE

Alberto M. Castro, MD
Gloria D. Lim, MD
Lawrence Marlon H. Pe, MD

*East Avenue Medical Center
Quezon City, Philippines*

Fine-needle aspiration biopsy

A valuable test for malignancy of orbital tumors

ABSTRACT

Objective

This study determined the effectiveness of fine-needle aspiration biopsy (FNAB) in detecting malignancy in orbital lesions compared with section biopsy. Its sensitivity, specificity, and positive predictive value were determined.

Methods

This is a nonrandomized, prospective, comparative study of 33 (20 males and 13 females, ages 11 months to 71 years) with orbital lesions who underwent FNAB. The cytologic results were correlated with the histologic results. Different pathologists who were blinded as to study lesions read the cytologic and histologic smears.

Results

Twenty-three patients whose smears had high yield of cells were included in the study. Excluded were 2 with poor yield smears, 3 hemorrhagic smears, and 5 without section biopsies of which 2 presented with pyogenic granuloma. FNAB is 87.5% sensitive and 100% specific, with a positive predictive value of 100%. No statistical difference was found between FNAB and section biopsy in detecting ocular malignancy ($p < 0.05$) in this study.

Conclusion

FNAB has a good sensitivity and specificity in diagnosing ocular malignancy and is a useful tool in the diagnosis of orbital tumors.

Correspondence to
Alberto M. Castro, MD
East Avenue Medical Center
East Avenue, Diliman
1104 Quezon City, Philippines
Tel. +63-2-3731685
E-mail: dr_albert_castro@yahoo.com

Keywords: *Fine-needle aspiration biopsy, section biopsy, malignancy, orbital tumors*

The authors have no proprietary or financial interest in any product used or cited in this study.

PHILIPP J OPHTHALMOL 2004; 29(4): 175-177

© PHILIPPINE ACADEMY OF OPHTHALMOLOGY

SECTION biopsy, the removal of the whole or a part of the mass, is considered the “gold standard” in the diagnosis of orbital lesions. An incisional or excisional biopsy is performed depending on the size of the mass. This diagnostic and therapeutic procedure is selected for tumors suspected to be malignant.

Fine-needle aspiration biopsy (FNAB) or aspiration-biopsy cytology is widely used for morphologic diagnosis of tumors.¹ It has the advantage of possibly obviating major surgeries. It requires the removal of a sample of cells using a fine needle to predict the nature of the entire lesion, assuming that the lesion is homogenous. It is a cytologic rather than a histologic technique. It has other advantages: it is easy to perform and does not require extensive preparations such as hospitalization or anesthesia, results are fast, and costs are lower. Reported complications include pain and anxiety, minor bleeding, vasovagal reaction, seizures, nerve damage, local anaphylaxis, and infection.¹

In this study we determined the effectiveness of FNAB in detecting malignancy in orbital lesions compared with section biopsy. We determined its sensitivity, specificity, and positive predictive value.

METHODOLOGY

Patients with orbital lesions who underwent FNAB at the Orbit Section of the Department of Ophthalmology East Avenue Medical Center from January 2001 to June 2003 were included into the study. Those who did not undergo section biopsy, or had poor yield or hemorrhagic smears were excluded.

FNAB was performed as follows: Computed-tomography (CT) plates were examined and the position of the mass

noted. The skin was cleansed with povidone iodine. No anesthetic was used. A gauge 23, 1.5-inch needle attached to a 10 cc disposable plastic syringe was carefully introduced into the lesion, avoiding blood vessels. After entering the mass, suction was applied and maintained with the syringe. The needle was moved in and out, in a cutting motion within the lesion, to obtain adequate sample. At the conclusion of the procedure, the suction was released, and the needle was pulled straight out. Sterile dressing was applied on the puncture site and pressure applied. Aspirates were smeared on a glass slide and fixed with 95% ethyl alcohol. Slides were stained with *Papanicolaou* and analyzed under a microscope.

A section biopsy was subsequently done under standard techniques. The cytologic results were correlated with the histologic results. Different pathologists who were blinded as to study lesions read the cytologic and histologic smears.

RESULTS

Thirty-three patients (20 males and 13 females, ages 11 months to 71 years) underwent FNAB but only 23 whose smears had high yield of cells were included. Excluded were 2 with poor yield smears, 3 hemorrhagic smears, and 5 without section biopsies, two of whom presented with pyogenic granuloma that responded to antibiotics.

Table 1 shows the comparison between the cytologic diagnosis from FNAB and the histologic diagnosis from the section biopsy. Eight of the cytologic results showed malignancy with one false negative. On the other hand, all 15 cases that had negative malignancy on section biopsy also showed negative on FNAB.

Results showed that FNAB is 87.5% sensitive and 100%

Table 1. Comparison between FNAB and section biopsy results.

| FNAB (Cytologic Diagnosis) | Section Biopsy (Histologic Diagnosis) | Number of Cases |
|--|--|-----------------|
| Positive for malignant cells. Cytomorphologic findings consistent with lymphoproliferative disorder. | Lymphoma | 2 |
| Positive for malignant cells. Cytomorphologic findings consistent with carcinoma, probably glandular in origin. | Adenoid cystic carcinoma | 1 |
| Positive for malignant cells. Cytomorphologic findings consistent with carcinoma. | Nasopharyngeal carcinoma | 2 |
| Positive malignant cells. Cytomorphologic findings consistent with malignant blue cell tumor. Considerations: 1) small cell CA 2) primitive neuroectodermal tumor (PNET)/Ewing's sarcoma. | Malignant tumor consistent with poorly differentiated adenocarcinoma | 1 |
| No malignant cells seen. Cytomorphologic findings consistent with epidermal inclusion cyst. | Epidermal inclusion cyst | 1 |
| No malignant cells seen. | Conjunctival cyst | 3 |
| No malignant cells seen. Lymphoproliferative disorder. Favor benign process. | Inflammatory pseudotumor | 5 |
| No malignant cells seen. | Squamous hyperplasia with keratosis and sclerosis | 1 |
| No malignant cells seen. Cytomorphologic findings consistent with a chronic inflammatory process. | Dermoid cyst | 4 |
| Positive for malignant cells. | Rhabdomyosarcoma | 1 |
| Positive malignant cells. | Small cell CA with neuroendocrine differentiation; consider metastatic small cell CA of the lung or primary Merkel tumor | 1 |
| No malignant cells seen. Cytomorphologic findings consistent with tumor of neurogenic origin. | Shwannoma (Neurilemoma) | 1 |

Table 2. Comparison of FNAB with incisional biopsy.

| | | Incisional Biopsy | | |
|---|---------------------|---------------------|---------------------|-------|
| F | | Positive Malignancy | Negative Malignancy | Total |
| N | Positive Malignancy | 7 | 0 | 7 |
| A | Negative Malignancy | 1 | 15 | 16 |
| B | Total | 8 | 15 | 23 |

specific, with a positive predictive value of 100% (Table 2). When compared with corresponding incisional biopsy using Fishers Exact Test, no statistical difference was found between FNAB and section biopsy in detecting ocular malignancy ($p < 0.05$).

DISCUSSION

FNAB is a well-recognized technique in the diagnosis of tumors of the head, neck, lung, in various abdominal and prostatic tumors, and more recently, in tumors of the bone and eyelid.² Remulla, et.al. found that FNAB was a useful technique in the diagnosis of retinoblastoma,³ which confirmed findings by Das et al. in 3 cases of retinoblastoma in children.⁴ These studies showed that FNAB is a useful tool in the diagnosis of orbital tumors, which can be performed as an outpatient procedure with minimal discomfort and cost to the patient. Cytologic results from the biopsy give a preliminary idea of whether the lesion is malignant or benign so that appropriate treatment can be planned before contemplating a more invasive procedure.

Our results showed that FNAB has high sensitivity and specificity for detecting ocular malignancy and that the concordance between the two procedures is good though the sample size is small. Other studies have shown similar results.²⁻⁵ Caution, however, must be exercised in the interpretation of cytologic results of FNAB.² The best indication for FNAB is detection of malignant orbital disease.⁵ It is not helpful in tumors or inflammatory disease with a high fibrous content.⁵ Lesions that are suspected pseudotumors are not recommended for FNAB since they are notoriously difficult to distinguish from well-differentiated lymphocytic malignant lymphoma even in histologic sections.⁵ For instance, one patient in this series showed cytomorphologic findings consistent with a lymphoproliferative disorder, which was confirmed with a histologic diagnosis of malignant lymphoma (Figure 1). However, 5 smears with the same cytomorphologic

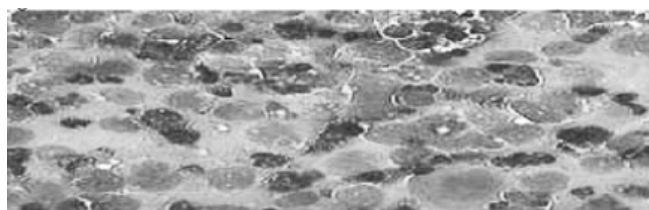


Figure 1. Cytomorphologic findings consistent with lymphoproliferative disorder showing large lymphoid cells with round to oval nuclei.

findings had a histologic diagnosis of inflammatory pseudotumor. In these cases, an incisional biopsy is recommended.

In our study, we detected 7 cases of malignant tumors by FNAB that correlated with the histologic diagnoses (Table 2). Only 1 case of lymphoproliferative disorder favoring reactive process on FNAB was diagnosed as Hodgkin's lymphoma. This supported previous studies on the difficulty of FNAB in differentiating lymphomas from inflammatory diseases.

FNAB is relatively safe. The concern about implanting tumor cells during the procedure is as old as aspiration biopsy itself.¹ There is no direct evidence that aspiration biopsy causes an increase in distant metastases or adversely affects the survival of the patients.¹ In our study, only one complication (retrobulbar hemorrhage because of a deep-seated retrobulbar mass) was encountered. The hemorrhage was appropriately managed and resolved after 7 days. To avoid serious complications, ultrasound-guided FNAB or use of other imaging techniques is recommended prior to or during the procedure. The positive yield will also be higher with less chance of hemorrhage.

In summary, fine-needle aspiration biopsy is a useful tool in the diagnosis of orbital tumors. It is 87.5% sensitive and 100% specific, with a positive predictive value of 100%. No statistical difference was found between FNAB and section biopsy in detecting ocular malignancy ($p < 0.05$) in this study of 23 cases.

References

1. DeMay, R.M. *The Art and Science of Cytopathology*, Vol. 2. Chicago: ASCP Press, 1996; 464-481.
2. Kennerdell JS, Dubois PJ, Dekker A, Johnson BL. CT-guided fine-needle aspiration biopsy of orbital optic nerve tumors. *Am J Ophthalmol* 1980; 87:491-496.
3. Remulla JC, Espiritu RB, Abelardo AD, et al. Fine-needle aspiration biopsy in the diagnosis of retinoblastoma. *Philipp J Ophthalmol* 1999; 24: 86-88.
4. Das DK, Das J, Chachra KL, Natarajan R. Diagnosis of retinoblastoma by fine-needle aspiration and aqueous cytology. *Diagn Cytopathol* 1989; 5: 203-206.
5. Kennerdell JS, Dekker A, Johnson BL, Dubois PJ. Fine-needle aspiration biopsy: its use in orbital tumors. *Ophthalmology* 1979; 97: 1315-1317.
6. Gupta S, Sood B, Gulati M, et al. Orbital mass lesions: US-guided fine-needle aspiration biopsy: experience in 37 patients. *Radiology* 1999; 213: 568-572.